

**THE EFFECTS OF INTRA-ARTICULAR SILICONE POLYMER ON
SYNOVIAL FLUID, SYNOVIAL TISSUE, AND ARTICULAR CARTILAGE IN
THE EQUINE MIDDLE CARPAL JOINT**

A Thesis

Submitted to the Graduate Faculty of the
Louisiana State University and
Agricultural and Mechanical College
in partial fulfillment of the
requirements for the degree of
Master of Science

In

The Interdepartmental Program in
Veterinary Medical Sciences through
the Department of Veterinary Clinical Sciences

by

Marilyn L. Rumbaugh
BS, University of Nevada, Reno, 1996
DVM, The Ohio State University, 1999
May, 2003

ACKNOWLEDGEMENTS

I would like to acknowledge Dr. Daniel J. Burba (major professor), Dr. Rustin M. Moore, and Dr. Giselle Hosgood, the members of my graduate committee. I am extremely grateful for all of their help.

I would like to acknowledge my co-investigators Dr. Daniel J. Burba, Dr. Joanne Tetens, Dr. Giselle Hosgood, Dr. Julian L. Oliver, Dr. Jamie Williams, and Dr. Casey J. LeBlanc. Their assistance was crucial to the completion of the study.

I extend my thanks to the Louisiana State University School of Veterinary Medicine VCS Corp Fund and the Equine Medicine and Surgery section for their financial support of this study.

I would also like to thank my parents, Dennis and Judy Rumbaugh, who have provided me with loving support throughout all my endeavors.

TABLE OF CONTENTS

ACKNOWLEDGEMENTS	ii
LIST OF TABLES	v
LIST OF FIGURES	vi
LIST OF ABBREVIATIONS	vii
ABSTRACT	viii
CHAPTER 1 – INTRODUCTION/REVIEW OF LITERATURE	1
1.1 Introduction	1
1.2 Anatomy of Synovial Joints	2
1.2.1 Synovial Membrane	2
1.2.2 Synovial Fluid	3
1.2.3 Articular Cartilage	3
1.3 Lubrication of Synovial Joints	5
1.4 Etiology and Classification of Clinical Joint Disease in Horses	6
1.5 Pathobiology of Synovial Membrane and Articular Cartilage	7
1.6 Intra-articular Treatment of Synovitis and Degenerative Joint Disease in Horses	8
1.6.1 Corticosteroids	8
1.6.2 Non-steroidal Anti-inflammatory Drugs	8
1.6.3 Hyaluronan	9
1.6.4 Polysulfated Glycosaminoglycans	9
1.6.5 Silicone	10
1.7 Use and Effects of Intra-articular Silicone	10
1.8 Migration of Liquid Silicone	13
1.9 Hypotheses for Present Study	13
1.10 References	14
CHAPTER 2 – THE EFFECTS OF INTRA-ARTICULAR SILICONE POLYMER ON SYNOVIAL FLUID, SYNOVIAL TISSUE, AND ARTICULAR CARTILAGE IN THE EQUINE MIDDLE CARPAL JOINT	18
2.1 Introduction	18
2.2 Materials and Methods	19
2.2.1 Horses	19
2.2.2 Experimental Protocol	20
2.2.3 Radiography	21
2.2.4 Synovial Fluid	21
2.2.5 Synovial Membrane	21
2.2.6 Articular Cartilage	22
2.2.7 Axillary Lymph Nodes	22
2.2.8 Statistical Analyses	23

2.3 Results	24
2.3.1 Heart Rate, Rectal Temperature, and Respiratory Rate	24
2.3.2 Joint Circumference, Effusion, and Lameness Examination	25
2.3.3 Radiography	27
2.3.4 Synovial Fluid	28
2.3.5 Synovial Membrane	29
2.3.6 Articular Cartilage	35
2.3.7 Axillary Lymph Nodes	36
2.4 Discussion	36
2.5 Product Information	43
2.6 References	44
SUMMARY	46
BIBLIOGRAPHY	48
VITA	52

LIST OF TABLES

Table 2.1. Mean \pm SD rectal temperature, heart rate, and respiratory rate for horses prior to injection (time 0) and 24 hours, 48 hours, and 72 hours after injection. _____25

Table 2.2. Significant clinical variables associated with treatment reflected by 95% confidence intervals (CI) of relative risk estimates that exclude 1.0. Where time is a confounder, the adjusted relative risk (RRa) estimate is reported. Where time was not a confounder, the crude relative risk (RRc) estimate is reported. _____26

Table 2.3. Frequencies of lameness, lameness following 60 second carpal flexion test, pain demonstrated with maximal carpal flexion, decreased range of motion, and effusion for saline-treated and silicone treated carpi prior to injection (0 hours) and serially from two hours to six weeks after injection. Two observers evaluated the categories at each time point. _____27

Table 2.4 Frequencies of histologic grades for synovial membrane, cartilage stained with hematoxyline and eosin (H & E), and cartilage stained with safranin-O from saline-treated and silicone-treated middle carpal joints. Frequencies of histologic grades for axillary lymph nodes from limbs with saline-treated and silicone-treated carpi. ____29

Table 2.5 Modes of histologic grades for synovial membrane, articular cartilage stained with hematoxylin & eosin (H&E), and articular cartilage stained with safranin-O from saline-treated and silicone-trated middle carpal joints. Modes of histologic grades for axillary lymph nodes from limbs with saline-treated and silicone-treated carpi. ____29

LIST OF FIGURES

Figure 2.1. Mean \pm SEM joint circumferences for silicone-treated and saline-treated carpi. An asterisk (*) denotes a significant ($p \leq 0.5$) increase in joint circumference for silicone-treated carpi over the circumference at time zero. There was no significant change over time for saline-treated carpi. _____ 26

Figure 2.2 Photomicrograph of synovial fluid from a treated middle carpal joint illustrating distinct cytoplasmic vacuoles (V) containing silicone within macrophages. Modified polychrome methylene blue-eosin stain. 198x magnification _____ 30

Figure 2.3. Photomicrograph of synovial membrane from a saline-treated joint that was graded 0. The synovium (S) is comprised of a single layer of cells. Hematoxylin & eosin. 20x magnification. Magnification bar is 50 μm . _____ 31

Figure 2.4. Photomicrograph of synovial membrane from a silicone-treated joint that was graded 1. There is slight hypertrophy/hyperplasia of the synovium (S). Hematoxylin & eosin. 20x magnification. Magnification bar is 50 μm . _____ 32

Figure 2.5. Photomicrograph of synovial membrane from a silicone-treated joint that was graded 2. There is hypertrophy/hyperplasia of the synovium (S) along with moderate accumulation of distended, vacuolated cells (V) containing silicone beneath the synovium. Hematoxylin & eosin. 20x magnification. Magnification bar is 50 μm . _____ 33

Figure 2.6. Photomicrograph of synovial membrane from a silicone-treated joint that was graded 3. There is hypertrophy/hyperplasia of the synovium (S) along with marked accumulation of distended, vacuolated cells (V) containing silicone beneath the synovium. Hematoxylin & eosin. 20x magnification. Magnification bar is 50 μm . _____ 34

Figure 2.7. Photomicrograph of articular cartilage that was graded 0. Hematoxylin & eosin. 20x magnification. Magnification bar is 50 μm . _____ 35

Figure 2.8. Photomicrograph of articular cartilage that was graded 0. Safranin O. 20x magnification. Magnification bar is 50 μm . _____ 36

LIST OF ABBREVIATIONS

CI – confidence interval

cs – centistokes

GAG - glycosaminoglycan

H & E – hematoxylin and eosin

HA – hyaluronan

IL - interleukin

mLs – milliliters

MMP – matrix metalloprotease

NSAID – non-steroidal anti-inflammatory drug

PG - prostaglandin

PSGAGs – polysulfated glycosaminoglycans

RRa – adjusted relative risk

RRc – crude relative risk

TNF – tumor necrosis factor

ABSTRACT

There is anecdotal documentation that intra-articular administration of liquid silicone is used as a lubricant for equine joints. Effects of silicone polymer on equine articular cartilage and synovial fluid have not been evaluated. The objectives were to characterize the effects of intra-articular administration of liquid silicone polymer on clinical, synovial fluid, and microscopic features in normal middle carpal joints of horses, and to determine if silicone migrates to the axillary lymph nodes. Eight adult horses were used in this study. Two mLs of 1,000 centistoke, medical-grade silicone was injected into one randomly selected middle carpal joint. The opposite middle carpal joint was injected with two mLs of 0.9% NaCl. Degree of effusion, range of motion, pain on flexion, joint circumference, and degree of lameness were determined prior to injection, at 2, 8, 12, 24, 48, and 72 hours after injection, and weekly for 6 weeks after injection. Radiographic examination, synovial fluid analysis, and microscopic examination of synovium, articular cartilage and axillary lymph nodes were performed at the conclusion of the study. Joint circumference for silicone-treated carpi was significantly greater ($p \leq 0.05$) than saline-treated carpi from eight to 336 hours after injection. There was a significant association between treated limbs and lameness, lameness after flexion, pain elicited upon maximal flexion of carpus and middle carpal effusion in treated limbs. Radiographic examination did not reveal the presence of osseous abnormalities; however, effusion was present in 4/8 silicone-treated carpi and 2/8 saline-treated carpi. Synovial fluid from silicone-treated and saline-treated carpi had normal protein concentrations and total nucleated cell counts. Synovial fluid from 5/8 silicone-treated carpi had refractile cytoplasmic vacuoles within macrophages. All silicone-treated carpi had synovial

hypertrophy with 7/8 silicone-treated carpi demonstrating accumulation of vacuolated cells containing silicone. Examination of articular cartilage from saline-treated and silicone-treated carpi did not reveal a significant difference. Silicone was not definitively demonstrated in any axillary lymph nodes. Administration of silicone into the middle carpal joint resulted in synovitis. A single administration of silicone polymer had no apparent effects on articular cartilage within six weeks of administration.

CHAPTER 1. INTRODUCTION/REVIEW OF LITERATURE

1.1 Introduction

Joint disease, defined here as a lesion in a joint resulting in lameness, is a major cause of unsoundness in horses (1). In one study, 42 percent of 1,042 horses examined for lameness were diagnosed with joint disease (2). Joint disease in horses can develop from various etiologies, including conformational faults, accidental joint trauma, infection, or repeated joint trauma associated with athletic use. Joint disease can present itself in various forms depending on the duration and extent of joint injury. Generally, joint disease is categorized according to the presence or absence of articular cartilage degeneration. Joint disease is often classified as a primary synovitis or as degenerative joint disease. Primary synovitis is characterized by inflammation of the soft tissue structures enclosing the articular surface along with a lack of radiographic evidence of osseous lesions. If there is radiographic evidence of joint disease, the diagnosis of degenerative joint disease is made.

The conventional therapeutic options for performance horses with joint disease include intra-articular administration of corticosteroids, systemic administration of polysulfated glycosaminoglycans (PSGAGs), systemic and/or intra-articular administration of hyaluronic acid, systemic administration of non-steroidal anti-inflammatory drugs (NSAIDs), and prolonged periods of rest (3). There is anecdotal documentation that intra-articular administration of liquid silicone is used occasionally as an intra-articular lubricant for equine joints. Despite the fact that there are conflicting results regarding the safety and efficacy of intra-articular liquid silicone in various species, it is used in Standardbred racehorses to treat osteoarthritis that has become

refractory to more conventional treatments; however, the effects of liquid silicone polymer on synovial fluid and articular cartilage in the equine middle carpal joint are not known.

1.2 Anatomy of Synovial Joints

A synovial or diarthrodial joint consists of the articulating surface of bones, the articular cartilage covering the bones, the periarticular soft tissues, the synovial membrane which lines the joint surfaces not covered by articular cartilage and the synovial fluid within the joint cavity. The joint allows movement and the transfer of load between bones. The components discussed here are the synovial membrane, synovial fluid, and articular cartilage.

1.2.1 Synovial Membrane - The synovial membrane is a vascular connective tissue that lines the inner surface of the joint which is not covered by articular cartilage. The synovial membrane contains two mesenchymal cells layers: the synovium (intima) and the subsynovium (subintima) (3, 4). The synovium is a thin (one to four synoviocytes thick), incomplete lining of synoviocytes in contact with synovial fluid (3, 4). The subintima is adjacent to the fibrous joint capsule and is principally composed of fibrous, areolar, or adipose tissue depending on location within the joint (4). The synovial membrane bears no true epithelium and lacks a conventional basement membrane; therefore, the synovium and subsynovium are a structural and functional continuum (5).

The synovial cells of the synovium are generally classified into two categories based on function. Type A cells are considered macrophagic and function to phagocytose and pinocytose (6). Type B cells are fibroblastic and secretory (5). These cells have

been shown to synthesize hyaluronan (HA) and low-molecular weight proteins that impart viscosity to synovial fluid, collagen, and proinflammatory mediators (5). A third type of synoviocyte, type C, has been reported to have function and structure between type A cells and type B cells, and it is believed that type C cells are a transitional form of synoviocyte (4, 5, 7).

Numerous blood vessels are present in the subintima and extend to within five to ten microns of the intimal surface (6). The rich blood supply in the subsynovial layer contributes to the formation of synovial fluid and allows for nutrient exchange and waste product removal within the joint (5).

1.2.2 Synovial Fluid - Synovial fluid is an ultrafiltrate of plasma with HA (from synoviocytes) added (6, 7). Synovial fluid normally contains 90% mononuclear cells (synovial lining cells, monocytes, and lymphocytes) and 10% polymorphonuclear leukocytes (6). The number of nucleated cells in normal equine synovial fluid is generally reported to be less than 500 cells/ μ L (6, 8). Synovial fluid is the medium through which the articular cartilage and intra-articular ligaments receive nutrients (7).

1.2.3 Articular Cartilage - Articular cartilage covers the subchondral bone plate. Cartilage has no nerves, vessels, or lymphatics, and it derives its nutrition from diffusion of nutrients present in synovial fluid (5). The water content in articular cartilage may be as high as 80% (6). On a dry weight basis, articular cartilage contains approximately 50% collagen, 35% proteoglycans, 10% glycoproteins, 3% mineral, and 1% lipid (6). Chondrocytes comprise up 1 to 12% of articular cartilage (by volume) (6).

Articular cartilage is divided into four distinct histological and biochemical layers or zones determined by chondrocyte shape and orientation (4, 5). The superficial zone

(also called the tangential or gliding zone) is the zone closest to the articular surface. It contains elongated cells oriented parallel to the joint surface. The middle (transitional zone) is deep to the superficial zone. The cells in this layer are rounded and randomly distributed. The next layer is the deep (radial) zone in which cells are arranged in columns perpendicular to the articular surface. The deepest layer (the layer adjacent to subchondral bone) is the calcified zone. Cells in this zone are heavily encrusted with hydroxyapatite crystals. The deep and calcified zones are separated by the tidemark, a line visible on histologic preparations, the function of which has not yet been elucidated.

Most (up to 90%) of the collagen in articular cartilage is type II; however, thirteen types of collagen have been isolated from the matrix (4, 6). The function of type II collagen, which is synthesized by chondrocytes, is to provide tensile strength to the cartilage (4-6).

Proteoglycans are broadly defined as composite molecules consisting of both protein and glycosaminoglycan (polysaccharide) components. They are the second major solid component of the articular cartilage matrix and occupy the spaces between the collagen fibrils (7). The primary proteoglycan of articular cartilage is aggrecan which interacts with HA to form aggregates (5). Aggrecan is highly negatively charged and binds with water forming a highly hydrated matrix which provides cartilage its compressive stiffness and ability to dissipate load (5).

The noncollagenous, nonproteoglycan glycoproteins constitute a small portion of articular cartilage. Although multiple glycoproteins have been identified, the function of the majority remains unclear (7).

Chondrocytes are responsible for extracellular matrix synthesis and are capable of elaborating proteolytic enzymes effecting degradation of extracellular matrix; therefore, maintenance of cartilage matrix involves the chondrocyte-mediated processes of synthesis and degradation (5, 6). Chondrocytes obtain their nutrients by diffusion from the synovial fluid. This is also the route through which metabolic waste products are removed (6). Chondrocyte metabolism is influenced by intrinsic and extrinsic mechanical influences (5).

1.3 Lubrication of Synovial Joints

Two main systems of cartilage-on-cartilage lubrication are accepted and well-described: a “weeping” (hydrostatic) system and a “boundary” system (5). Boundary lubrication functions at low loads and is accomplished primarily by lubricin (a synovial glycoprotein) and HA. These molecules bind to opposing articular cartilage surfaces and prevent their direct contact under low loads.

At high loads, boundary lubrication fails because the lubricants are sheared off of the articular cartilage, and the joint is lubricated by hydrostatic lubrication (7). Hydrostatic lubrication is effected by a thin film of water liberated from the cartilage matrix when it is compressed. The water is squeezed onto the cartilage surfaces, immediately peripheral to the zone of contact. It has been proposed that the fluid is trapped on the surface of the articular cartilage when HA plugs the cartilage pores (“boosted lubrication”) (7). The concentrated pools on the surface of the cartilage decrease the coefficient of friction. When the compressive force is released, the cartilage expands and water is drawn back into the matrix.

Adequate lubrication of the soft tissue structures within the joint is also important. In fact, soft tissues contribute the majority of frictional resistance to joint movement because the energy requirements for the stretching of articular soft tissues is 100 times that of the frictional resistance of opposing cartilage surfaces (6). The synovium is lubricated by a thin film of synovial fluid rich in HA (5). Hyaluronan in the synovial fluid adsorbs to the synovial membrane and allows the synovial membrane to move easily (6).

1.4 Etiology and Classification of Clinical Joint Disease in Horses

Arthritis is a term used in equine medicine and surgery in reference to a number of joint afflictions. Etiologic factors can be divided into three main groups: traumatic, developmental, and infectious. As the severity of arthritis increases, or if treatment is unsuccessful, the likelihood of the development of degenerative joint disease escalates. The term degenerative joint disease is used to represent a group of disorders characterized by deterioration of the articular cartilage, accompanied by changes in the bone and soft tissues of the joint (6).

There are three pathogenic mechanisms hypothesized for initiation and propagation of degenerative joint disease (6)5,6]. The first is based on the major role of physical forces and biomaterial failure of articular cartilage (biomechanical). The second category attributes a major part of the disease to failure of chondrocyte responses to insult (biochemical). In other words, injured chondrocytes release proteolytic enzymes which cause cartilage fibrillation and breakdown of proteoglycans. The third category considers periarticular bony remodeling, synovial responses, microfractures, vascular changes, and

other extra-articular cartilaginous factors as primary problems, with cartilage alterations being secondary.

1.5 Pathobiology of Synovial Membrane and Articular Cartilage

Diseases of the soft tissues of the joint can occur as a primary entity (primary synovitis), or the synovium can be secondarily inflamed as a result of the release of cartilage-degradative products (secondary synovitis) (2). The initiating event may not be obvious, and diseases of synovium and cartilage can occur concomitantly. As previously stated, the normal turnover of the extracellular matrix of the articular cartilage is regulated by chondrocytes under the control and influence of cytokines and mechanical stimuli. Articular cartilage degradation takes place when there is an imbalance in synthesis and degradation (7).

In the initial state of inflammation, disruption of the blood-synovial barrier allows non-specific mediators of inflammation to enter the joint (4). These non-specific mediators include kinin, histamine, complement, plasminogen, and trypsin (4). The non-specific inflammatory mediators cause nucleated cells (monocytes and polymorphonuclear cells) to enter the joint cavity, and they activate macrophages, synoviocytes, and connective tissue cells to secrete pro-inflammatory cytokines such as interleukin (IL)-1 and tumor necrosis factor (TNF)- α . (4, 6, 9-12). These cytokines are secreted in excess of the concentrations required for normal metabolic homeostasis in the joint, and they work synergistically (4, 6). Both IL-1 and TNF induce proteoglycan depletion in articular cartilage by increasing the rate of proteoglycan depletion, decreasing synthesis by the chondrocytes, or both (4, 6, 10, 13). This is accomplished, in

part through the stimulation of matrix metalloproteinase (MMP) and prostaglandin (PG) E₂ synthesis (4, 6, 13).

1.6 Intra-articular Treatment of Synovitis and Degenerative Joint Disease in Horses

Degenerative joint disease in horses is often treated with intra-articular, intravenous, intramuscular, and/or oral medications. The use of intra-articular medications will be discussed here.

1.6.1 Corticosteroids – Corticosteroids exert their potent anti-inflammatory effects by: (1) stabilization of lysosomal membranes, with a subsequent decrease in the release of lysosomal enzymes, (2) inhibition of inflammatory cell movement into an inflamed area, and (3) inhibition of the cyclooxygenase and lipoxygenase pathways via the inhibition of phospholipase A₂ (7, 14) Intra-articular corticosteroids have been studied extensively to determine if the overall effect on the synovial structures is beneficial or deleterious. The overall effect depends on numerous factors including dose, type of steroid utilized, level of pre-existing joint disease, and intensity of post-administration exercise (7, 15-18).

1.6.2 Non-steroidal Anti-inflammatory Drugs - Non-steroidal anti-inflammatory drugs (NSAIDs) exert their effect by inhibiting the conversion of arachidonic acid to endoperoxidase by cyclooxygenase. Although numerous NSAIDs are available for systemic use, NSAIDs are not commonly used intra-articularly in the horse.

The NSAID bufexamac is available as an intra-articular suspension. Bufexamac has been evaluated for its effects on amphotericin B-induced arthritis in horses where it was shown to be effective in reducing the clinical signs of lameness and the activity of the lysosomal enzyme, β -glucuronidase (19).

1.6.3 Hyaluronan - Hyaluronan (HA), also called hyaluronic acid, is a linear polydisaccharide and polyionic nonsulfated glycoaminoglycan (GAG). (7) Endogenous HA is synthesized by synoviocytes and chondrocytes. (7) HA is responsible for the viscosity of synovial fluid and is responsible for lubrication of the synovial membrane and articular cartilage. The concentration of endogenous HA varies between species and between joints of an individual. (8)

The mechanism of action of exogenously administered HA has not been firmly established. It is theorized that exogenous HA may supplement the actions of depleted or depolymerized endogenous HA, or it may modulate the increased synthesis of endogenous HA. (7) Clinically achievable concentrations of HA have been shown to decrease PGE₂ synthesis in cultured equine synoviocytes stimulated with lipopolysaccharide. (20)

1.6.4 Polysulfated Glycosaminoglycans - Polysulfated glycosaminoglycans (PSGAGs) are polysulfated polysaccharides believed to have chondroprotective effects (7). PSGAGs have been shown to inhibit enzymes which result in cartilage destruction (6, 21). PSGAGs have also been shown to directly inhibit prostaglandin synthesis and to stimulate the synthesis of sodium hyaluronate (7). The results of studies investigating the effect of PSGAGs on proteoglycan degradation and synthesis are contradictory (22-24).

Research has demonstrated an increased risk of joint infection following intra-articular administration of PSGAGs. The administration of PSGAGs into the equine middle carpal joint has been shown to potentiate a subinfective dose of *Staphylococcus aureus* (25, 26). This is believed to occur through the inhibition of complement activity (7, 27). Therefore, PSGAGs are usually administered intramuscularly.

1.6.5 Silicone - Liquid silicone is occasionally used as an exogenous lubricant in equine joints (3). It is used in Standardbred racehorses, often in conjunction with a corticosteroid, to treat osteoarthritis that has become refractory to more conventional treatments. Controlled studies evaluating its efficacy have not been published.

1.7 Use and Effects of Intra-articular Silicone

Silicones are long-chained polymers of dimethyl siloxane and may form a liquid, resin, or solid depending on the length of the chain (28). Silicone fluid is chemically inert, hydrophobic, has low volatility, resists decomposition by heat, and has low surface tension (29). The viscosity of liquid silicone ranges from 20 to 1,000 centistokes (cs) (1 cs = viscosity of water). Medical grade silicone has been used for human and veterinary reconstructive surgery, for the lubrication of prosthetic eyeballs, for the prevention of pleural and peritoneal adhesions, for human breast augmentation, and for exogenous lubrication of joints (30)-20].

Helal and Karadi reported on the use of liquid silicone for the lubrication of joints in 1968 (30). These authors injected 200 cs liquid silicone into rat and rabbit stifles. Gross and histologic inspections were performed at intervals beginning at one week after injection and concluding at four months after injection. According to these investigators, there were no abnormalities detected. A report of a human clinical trial was also published in 1968 where the same liquid silicone (200 cs) was injected into 214 osteoarthritic or rheumatoid joints in 152 people (30). A variety of synovial joints were injected, excluding the temporomandibular joint, joints of the spine, and terminal interphalangeal joints. Because the authors likened the use of silicone in an arthritic joint to the “oiling of a creaky hinge”, recordings with the aid of a microphone held against the

skin were made to record the change in joint crepitus before and after injection. The authors reported that there was a subjective improvement in 75% of injected joints, and previously detected crepitation was no longer present immediately following silicone injections.

A study published in 1970 reported the use of liquid silicone with a viscosity of 50 cs in 11 dogs' stifles (31). Results of a human clinical trial using 200 cs silicone was reported at the same time (31). In the dogs, one stifle received silicone whereas the opposite joint was injected with saline and served as a control. In nine of the dogs, a cartilage defect was created prior to injection of silicone or saline. The authors reported all dogs limped less on the silicone-injected limb. In the human clinical trial, the authors claimed a subjective improvement (less pain) in 89% of 997 silicone-injected joints. These authors concluded that the silicone acted as an excellent exogenous lubricant. They hypothesized that the silicone remained in the joint for approximately four months because this was the average length of time that people experienced the improvement.

Donahue, et al. attempted to determine the length of time that silicone remained within the joint space (32). Liquid silicone polymers of different viscosities, 350 cs and 1000 cs, were injected into rabbit stifle joints. The rabbits were euthanatized and histopathology was performed one, three, seven, 21, 42, and 90 days after injection. Silicone was present in synovial fluid at 42 days after injection, but no silicone was recovered from synovial fluid three months after injection. In contrast to a previous study (30) which reported no histologic abnormalities following injection of silicone into rabbit stifles, Donahue, et al. reported no gross histologic changes were present in the joint; however, histologic abnormalities were present as soon as the first day following

silicone injection (32). These included vacuolated phagocytic histiocytes, multinucleated giant cells and fibrous connective tissue in the subsynovium.

In contrast to the findings of Donahue, et al., Wright, et al. reported that silicone injected into rabbit stifles was not detectable in synovial fluid within 48 hours of injection (33). These authors found no histologic abnormalities up to six weeks after injection. Results of a clinical trial in 25 people that was published at the same time indicated no significant reduction in pain scores or range of motion in joints that received silicone injections. In addition, three out of 30 people demonstrated a “synovial reaction” that included heat, swelling, and moderate to severe pain in the treated joint. These authors felt that the silicone did not serve as a good joint lubricant and that the improvements seen in prior studies may have been due to a placebo effect.

In 1967, Riddle and Wheat reported the effects of intra-articular liquid silicone on the equine synovial membrane (28). Four young adult horses with no clinical evidence of pre-existing joint disease were euthanatized following injection of 10 ml of 350 cs liquid silicone into the middle carpal joints of each horse. One horse was euthanatized at 72 hours after injection, two horses were euthanatized two weeks after injection, and one horse was euthanatized one month after injection. Gross and microscopic examinations of the middle carpal joints revealed a granulomatous reaction in the synovial membranes in all horses. The authors reported thickening of the synovial membrane and macrophage infiltration with clear vacuoles.

1.8 Migration of Liquid Silicone

The use of silicone as a biomaterial in human medicine and surgery can result in silicone-related disease. The body's response depends on the physical state of the silicone (liquid, gel, solid) and the route of migration (local, lymphatic, hematogenous).

Liquid silicone injected into the soft tissues of the human body for cosmetic purposes has been found to migrate subcutaneously and cause "silicone granulomas" which are areas of tissue infiltration by silicone-containing histiocytes (34-37).

Chronic, granulomatous hepatitis was diagnosed in three people after subcutaneous injection of liquid silicone (38). Silicone fluid deposition has also been demonstrated in the spleen, liver, adrenal, and kidneys of mice after subcutaneous injections of liquid silicone (39, 40).

Silicone lymphadenopathy due to administration of liquid silicone has been reported almost exclusively in axillary lymph nodes after breast augmentation (34). Tissue reaction in lymph nodes is similar to the reaction seen following soft tissue migration. Foreign body giant cells may be seen; however, they are relatively rare (34).

Silicone may enter the blood stream from soft tissue injection sites or by direct intravascular injection (34, 38). A case of acute, fatal pulmonary edema was reported following the inadvertent intravascular injection of liquid silicone (38). Silicone pulmonary microemboli have also been reported in patients after cardiopulmonary bypass surgery, in which silicone has been used as an antifoam agent (41).

1.9 Hypotheses for Present Study

Intra-articular administration of sterile liquid silicone will incite a mild, acute but transient synovitis in the equine middle carpal joint. Intra-articular administration of

sterile liquid silicone will have no detrimental effects on articular cartilage or synovial membrane in the equine middle carpal joint within six weeks after administration.

Silicone will migrate to the ipsilateral axillary lymph node following administration into the middle carpal joint.

1.10 References

1. Rosedale PD, et al. Epidemiological study of wastage among racehorses 1982 and 1983. *Vet Rec* 1985; 116(3): p. 66-9.
2. Todhunter RJ, Lust G. Pathophysiology of Synovitis: Clinical Signs and Examination in Horses. *Compend Contin Educ Pract Vet* 1990; 12(7): p. 980-992.
3. McIlwraith CW. Current concepts in equine degenerative joint disease. *J Am Vet Med Assoc* 1982; 180(3): p. 239-50.
4. Palmer JL, Bertone AL. Joint structure, biochemistry and biochemical disequilibrium in synovitis and equine joint disease. *Equine Vet J* 1994; 26(4): p. 263-77.
5. Caron JP. Synovial Joint Biology and Pathobiology. In: *Equine Surgery*. Auer JA, Stick JA, Editors. 1999, W.B. Saunders Company: Philadelphia. p. 665-678.
6. McIlwraith CW, Trotter GW. *Joint Disease in the Horse*. 1996, Philadelphia: W.B. Saunders Company.
7. McIlwraith CW. Diseases of Joint, Tendons, Ligaments, and Related Structures. In: *Adams' Lameness in Horses*. Stashak TS, Editor. 2002, Lippincott Williams & Wilkins: Baltimore. p. 459-644.
8. Van Pelt R. Properties of Equine Synovial Fluid. *J Am Vet Med Assoc* 1962; 141(9): p. 1051-1061.
9. Billingham RC, Fretz PB, Gordon J R. Induction of intra-articular tumour necrosis factor during acute inflammatory responses in equine arthritis. *Equine Vet J* 1995; 27(3): p. 208-16.
10. Todhunter PG, et al. Immunohistochemical analysis of an equine model of synovitis-induced arthritis. *Am J Vet Res* 1996; 57(7): p. 1080-93.
11. Spiers S, et al. Cellular sources of proteolytic enzymes in equine joints. *Equine Vet J* 1994; 26(1): p. 43-7.

12. Alwan WH, et al. Interleukin-1-like activity in synovial fluids and sera of horses with arthritis. *Res Vet Sci* 1991; 51(1): p. 72-7.
13. Richardson DW, Dodge GR. Effects of interleukin-1 beta and tumor necrosis factor-alpha on expression of matrix-related genes by cultured equine articular chondrocytes. *Am J Vet Res* 2000; 61(6): p. 624-30.
14. Moses VS, et al. Effects of anti-inflammatory drugs on lipopolysaccharide-challenged and -unchallenged equine synovial explants. *Am J Vet Res* 2001; 62(1): p. 54-60.
15. Chunekamrai S, et al. Changes in articular cartilage after intra-articular injections of methylprednisolone acetate in horses. *Am J Vet Res* 1989; 50(10): p. 1733-41.
16. Foland JW, et al. Effect of betamethasone and exercise on equine carpal joints with osteochondral fragments. *Vet Surg* 1994; 23(5): p. 369-76.
17. Frisbie DD, et al. Effects of triamcinolone acetonide on an in vivo equine osteochondral fragment exercise model. *Equine Vet J* 1997; 29(5): p. 349-59.
18. Trotter GW, et al. Effects of intra-articular administration of methylprednisolone acetate on normal equine articular cartilage. *Am J Vet Res* 1991; 52(1): p. 83-7.
19. Suominen MM, et al. Effects of intra-articular injections of bufexamac suspension on amphotericin B-induced aseptic arthritis in horses. *Am J Vet Res* 1999; 60(12): p. 1467-73.
20. Frean SP, Lees P. Effects of polysulfated glycosaminoglycan and hyaluronan on prostaglandin E2 production by cultured equine synoviocytes. *Am J Vet Res* 2000; 61(5): p. 499-505.
21. May SA, Hooke RE, Lees P. The effect of drugs used in the treatment of osteoarthritis on stromelysin (proteoglycanase) of equine synovial cell origin. *Equine Vet J Suppl* 1988(6): p. 28-32.
22. Caron JP, Eberhart SW, Nachreiner R. Influence of polysulfated glycosaminoglycan on equine articular cartilage in explant culture. *Am J Vet Res* 1991; 52(10): p. 1622-5.
23. Caron JP, Toppin DS, Block JA. Effect of polysulfated glycosaminoglycan on osteoarthritic equine articular cartilage in explant culture. *Am J Vet Res* 1993; 54(7): p. 1116-21.
24. Glade MJ. Polysulfated glycosaminoglycan accelerates net synthesis of collagen and glycosaminoglycans by arthritic equine cartilage tissues and chondrocytes. *Am J Vet Res* 1990; 51(5): p. 779-85.

25. Gustafson SB, et al. Further investigations into the potentiation of infection by intra-articular injection of polysulfated glycosaminoglycan and the effect of filtration and intra-articular injection of amikacin. *Am J Vet Res* 1989; 50(12): p. 2018-22.
26. Gustafson SB, McIlwraith CW, Jones RL. Comparison of the effect of polysulfated glycosaminoglycan, corticosteroids, and sodium hyaluronate in the potentiation of a subinfective dose of Staphylococcus aureus in the midcarpal joint of horses. *Am J Vet Res* 1989; 50(12): p. 2014-7.
27. Rashmir-Raven AM, et al. Inhibition of equine complement activity by polysulfated glycosaminoglycans. *Am J Vet Res* 1992; 53(1): p. 87-90.
28. Riddle WE, Jr., Wheat JD. Liquid silicone for intra-articular use in the horse. *J Am Vet Med Assoc* 1967; 155(8): p. 1367-9.
29. Braley SA. The use of silicones in plastic surgery. A retrospective view. *Plast Reconstr Surg* 1973; 51(3): p. 280-8.
30. Helal B, Karadi BS. Artificial lubrication of joints: use of silicone oil. *Ann Phys Med* 1968; 9(8): p. 334-40.
31. Helal B, Cozen L, Kramer L. Silicone injection of joints. Experimental and clinical trials. *Int Surg* 1970; 54(5): p. 317-22.
32. Donahue WC, Nosanchuk JS, Kaufer H. Effect and fate of intra-articular silicone fluid. *Clin Orthop* 1971; 77: p. 305-10.
33. Wright V, et al. Evaluation of silicone as an artificial lubricant in osteoarthrotic joints. *Br Med J* 1971; 2(758): p. 370-3.
34. Travis WD, Balogh K, Abraham JL. Silicone granulomas: report of three cases and review of the literature. *Hum Pathol* 1985; 16(1): p. 19-27.
35. Guerrissi J, Bejar A. Massive injections of adulterated liquid silicone: local complications and development of autoimmune diseases. *Ann Plast Surg* 1998; 41(5): p. 572-3.
36. Allevato MA, et al. Complications following industrial liquid silicone injection. *Int J Dermatol* 1996; 35(3): p. 193-5.
37. Bigata X, et al. Adverse granulomatous reaction after cosmetic dermal silicone injection. *Dermatol Surg* 2001; 27(2): p. 198-200.
38. Ellenbogen R, Rubin L. Injectable fluid silicone therapy. Human morbidity and mortality. *Jama* 1975; 234(3): p. 308-9.

39. Ben-Hur N, et al. Local and systemic effects of dimethylpolysiloxane fluid in mice. *Plast Reconstr Surg* 1967; 39(4): p. 423-6.
40. Rees TD, et al. Visceral response to subcutaneous and intraperitoneal injections of silicone in mice. *Plast Reconstr Surg* 1967; 39(4): p. 402-10.
41. Orenstein J M, et al. Microemboli observed in deaths following cardiopulmonary bypass surgery: silicone antifoam agents and polyvinyl chloride tubing as sources of emboli. *Hum Pathol* 1982; 13(12): p. 1082-90.

CHAPTER 2 - THE EFFECTS OF INTRA-ARTICULAR SILICONE POLYMER ON SYNOVIAL FLUID, SYNOVIAL TISSUE, AND ARTICULAR CARTILAGE IN THE EQUINE MIDDLE CARPAL JOINT

2.1 Introduction

Joint disease is a major cause of lameness in horses (1). In one study, 42 percent of 1,042 horses examined for lameness were diagnosed with joint disease (2). The conventional therapeutic options for performance horses with joint disease include intra-articular administration of corticosteroids, systemic administration of PSGAGs, systemic and/or intra-articular administration of hyaluronic acid, systemic administration of NSAIDs, and prolonged periods of rest (3). There is anecdotal documentation that intra-articular administration of liquid silicone is used occasionally as an exogenous intra-articular lubricant for equine joints.

Silicones are long-chained polymers of dimethyl siloxane and may form a liquid, resin, or solid depending on the length of the chain (4). Liquid silicone is chemically inert, hydrophobic, has low volatility, resists decomposition by heat, and has low surface tension (5). Liquid silicone has been used as a joint lubricant in human medicine (6-8). In 1967, Riddle and Wheat reported the effects of intra-articular liquid silicone on the equine synovial membrane. Four young adult horses with no clinical evidence of pre-existing joint disease were euthanatized after injection of liquid silicone polymer (350 cs) into the middle carpal joints of each horse. One horse was euthanatized 72 hours after injection, two horses were euthanatized two weeks after injection, and one horse was euthanatized one month after injection. Gross and microscopic examinations of the middle carpal joints revealed a granulomatous reaction in the synovial membranes in all horses. To our knowledge, the effects of silicone polymer on equine articular cartilage

and synovial fluid have not been evaluated. The effect of intra-articular silicone on articular cartilage, synovial fluid, and synovial membrane is unknown. Whether or not silicone migration occurs following intra-articular injection in horses is also unknown.

We hypothesized that intra-articular administration of sterile liquid silicone would incite a mild, acute but transient synovitis in the equine middle carpal joint. We hypothesized that intra-articular administration of sterile liquid silicone would have no detrimental effects on articular cartilage or synovial membrane in the equine middle carpal joint within six weeks after administration. We hypothesized that liquid silicone would migrate to the ipsilateral axillary lymph node following administration into the middle carpal joint.

The objectives of this study were to: (1) characterize the effects of intra-articular administration of liquid silicone polymer on clinical, synovial fluid, and microscopic features the synovial membrane and articular cartilage of normal middle carpal joints of horses, and (2) determine whether or not silicone migrates to the axillary lymph nodes following injection into the middle carpal joint in horses.

2.2 Materials and Methods

2.2.1 Horses - This study was approved by the Louisiana State University Institutional Animal Care and Use Committee. Eight healthy adult horses (four geldings, four mares) of various breeds ranging in age from five to 10 years were used in this study. Horses were considered free of middle carpal joint disease based on complete physical and lameness examinations, and radiographic examination. Horses were housed in a box stall for the first 72 hours of the study. For the remainder of the study, horses were housed in a pasture.

2.2.2 Experimental Protocol - Each horse was sedated with xylazine HCl^a (0.2 mg/kg IV). Treatments were randomly assigned to the limbs. For each limb, after aseptic preparation of the skin, a middle carpal joint arthrocentesis was performed to obtain synovial fluid for baseline analysis. Prior to removal of the needle, two mLs of 1,000 centistoke (cs) silicone^b (silicone-treated) or two mLs of 0.9% NaCl (saline-treated) was injected into either middle carpal joint.

Heart rate, respiratory rate, and rectal temperature were recorded immediately prior to injection, 24, 48 and 72 hours after injection.

Degree of effusion (0 = none, 1 = mild, 2 = moderate, 3 = severe), range of motion (normal vs. reduced), pain on maximal flexion of the carpus (none vs. present), joint circumference (cm), and degree of lameness using a modification of the standard American Association of Equine Practitioners grading system (9) (0 = none, 1 = difficult to observe and inconsistent, 2 = difficult to observe and consistent, 3 = moderately discernible, 4 = obvious lameness with full weight bearing, 5 = non-weight bearing) were determined by two investigators blinded to treatment prior to injection, at two, eight, 12, 24, 48, and 72 hours after injection, and weekly for six weeks after injection. Lameness examination consisted of examination at a trot in hand in a straight line prior to and following a one-minute carpal flexion test. Joint circumference was measured using a tape measure placed 3.5 cm distal to the accessory carpal bone.

Radiographic examination of each middle carpal joint was repeated at the conclusion of the study. Horses were euthanized at the conclusion of the study with sodium pentobarbital^c (100 mg/kg IV). Axillary lymph nodes, synovial fluid, synovium, articular cartilage, and subchondral bone were collected for histologic evaluation.

2.2.3 Radiography - Radiographic examination at baseline and six weeks after injection included dorsopalmar, lateromedial, dorsomedial-palmarolateral oblique, dorsolateral-palmaromedial oblique, and flexed lateromedial views. Radiographic interpretation was performed by an investigator blinded to limb treatment. Radiographs were evaluated for the presence of joint effusion, synovial thickening, periarticular osteophytes, enthesiophytes, subchondral irregularities, erosions or cysts, decreased or asymmetric joint space, bone destruction, air/gas in the joint space, and extracapsular thickening/swelling.

2.2.4 Synovial Fluid - Synovial fluid was collected from each middle carpal joint via arthrocentesis immediately after euthanasia. Synovial fluid (>0.5 mL) was placed into glass tubes containing EDTA. Synovial fluid analysis consisted of determination of red blood cell and nucleated cell counts^d, assessment of color, assessment of clarity, total protein concentration, and mucin clot quality. Total protein concentration was determined by a refractometer. Mucin clot tests, a semi-quantitative measure of hyaluronate concentration, were conducted by adding one mL of joint fluid into five to ten mLs of acetic acid. The solutions were mixed gently and observed for clot formation. Cytospins of the joint fluid were made by adding three to four drops of saline and one drop of 22% bovine serum albumin to one to two drops of joint fluid. The samples were then spun^e at 1,000 revolutions per minute for six minutes. After staining with a modified polychrome methylene blue-eosin stain^f, cytologic evaluation was performed by an investigator blinded to limb treatment.

2.2.5 Synovial Membrane - Synovium from the dorsomedial aspect of each middle carpal joint was harvested immediately after euthanasia and fixed in 10%

formalin. Following formalin fixation, the tissue was imbedded in paraffin, sectioned, and stained with hematoxylin and eosin (H & E). Specimens were examined by an investigator blinded to limb treatment. The synovium was graded, using a scale of 0 (normal), 1 (mild hyperplasia/hypertrophy), 2 (hyperplasia/hypertrophy + mild to moderate accumulation of vacuolated cells), and 3 (hyperplasia/hypertrophy + extensive accumulation of vacuolated cells).

2.2.6 Articular Cartilage - Immediately after euthanasia, the third carpal bone was disarticulated and fixed in 10% formalin. Following formalin fixation, articular cartilage from the radial facet of the third carpal bone was imbedded in paraffin, sectioned, and stained with safranin-O-fast green to assess matrix alteration. Additional samples were stained with H & E. Specimens were examined by an investigator blinded to limb treatment. Articular cartilage stained with safranin O was graded, using a scale of 0 (normal), 1 (mild interterritorial matrix staining), and 3 (moderate interterritorial matrix staining). Articular cartilage stained with H & E was graded, using a scale of 0 (normal), 1 (surface fibrillation), and 2 (fibrillation + clefts).

2.2.7 Axillary Lymph Nodes - Axillary lymph nodes were harvested from each leg immediately after euthanasia and fixed in 10% formalin. Following formalin fixation, the lymph nodes were imbedded in paraffin, sectioned, and stained with H & E. Lymph nodes were examined by an investigator blinded to limb treatment. Specimens were assessed for the microscopic presence of silicone and graded using a scale of 0 (normal), 1 (mild accumulation of vacuolated cells in the lymph nodes sinuses), and 2 (moderate accumulation of vacuolated cells in the lymph nodes sinuses).

2.2.8 Statistical Analyses - The joint circumference was found to follow a normal distribution using the Shapiro-Wilk statistic with failure to reject the null hypothesis of normality at $p \leq 0.05$. The effect of time and treatment (silicone vs. saline) was evaluated using a mixed linear model accounting for the random variance of horse and the repeated measurements over time. The model was first run including evaluator as an effect. With failure to find an effect of evaluator, the data was pooled and rerun. Where there were significant interaction of time and treatment at $p \leq 0.05$, pre-determined multiple comparisons were made within each treatment to time zero using least squares means. Since the treatments behaved differently across time, they were considered different and no further evaluation was required. Type I error was maintained at 0.05 for multiple comparisons. Thus, where a difference is noted, $p \leq 0.05$. The circumference is summarized as mean \pm SEM.

The mean \pm SD for rectal temperature, heart rate, and respiratory rate were calculated for each time point.

The categorical variables (lameness, lameness after carpal flexion, pain elicited by carpal flexion, effusion, and range of motion) were collapsed into dichotomous categories (present or absent). The data was first explored to evaluate for an effect of evaluator, controlling for time and treatment using Cochran Mantel-Haenzel methods for repeated categorical data. Since there was no effect of evaluator at $p < 0.05$, the data was pooled. The relative risk was calculated, and used as a measure of association between administration of silicone and the measured outcome. The data was stratified on time to evaluate for possible confounding of time. The homogeneity of strata was evaluated using the Breslow day statistic. Where there was nonhomogeneity of strata at $p \leq 0.05$,

and the crude and Mantel-Haenszel adjusted relative risk differed by more than 10%, time was considered a confounder, and the adjusted Mantel-Haenszel relative risk was reported. Where time was not a confounder, the crude relative risk was reported.

The histologic grades for synovial membrane, articular cartilage, and axillary lymph nodes are reported as frequencies and the mode (most frequent score) is used to summarize the data. The distribution of scores for histologic assessment of synovium, lymph nodes, and articular cartilage were compared between saline-treated and silicone-treated carpi using Cochran-Mantel Haenszel methods, controlling for repeated measurements on each horse. A significant difference in the distribution of the scores was determined at $p \leq 0.05$.

The frequency of the presence versus absence of joint effusion on radiographs between saline-treated and silicone-treated carpi was compared using Fisher's Exact test with significance determined at $p \leq 0.05$ against a two-sided hypothesis. The frequency of the presence of an abnormal versus normal cell count, and the presence of a good or fair mucin clot on synovial analysis was compared similarly.

PROC UNIVARIATE, PROC MIXED and PROC FREQ^g were used for the analysis.

2.3 Results

2.3.1 Heart rate, rectal temperature, and respiratory rate - The mean \pm SD heart rate, rectal temperature, and respiratory rate were normal at all time points (Table 2.1).

Table 2.1. Mean \pm SD rectal temperature, heart rate, and respiratory rate for horses prior to injection (time 0) and 24 hours, 48 hours, and 72 hours after injection.

Time	Temperature (° F)	Heart Rate (beats/min)	Respiratory Rate (breaths/min)
0	99.1 \pm 0.92	40.0 \pm 3.02	14.5 \pm 4.75
24	99.5 \pm 0.73	38.5 \pm 2.98	11.5 \pm 4.50
48	99.5 \pm 0.67	40.0 \pm 4.28	12.5 \pm 2.56
72	99.2 \pm 0.59	38.5 \pm 3.66	12.0 \pm 4.28

2.3.2 Joint Circumference, Effusion, and Lameness Examination - There was a significant increase in joint circumference for silicone-treated carpi from eight hours after injection to two weeks after injection (Figure 2.1). Prior to eight hours and beyond two weeks, the joint circumference for silicone-treated carpi was not different from the circumference at time zero. There was no significant change in joint circumference over time for saline-treated carpi.

There was a significant association between silicone-treated limbs and lameness, lameness after flexion, pain elicited upon maximal flexion of carpus, and middle carpal effusion in silicone-treated limbs (Table 2.2). The greatest association was found between silicone treatment and effusion; silicone-treated middle carpal joints had 5.25 times more risk of developing effusion when compared to saline-treated middle carpal joints. Time was found to be a confounder for effusion and pain elicited by maximal carpal flexion. There was no association between treatment and decreased range of motion during carpal flexion. The frequencies of the presence of lameness, lameness following 60 second carpal flexion test, pain demonstrated with carpal flexion, decreased range of motion, and effusion for saline-treated and silicone-treated carpi are listed in Table 2.3.

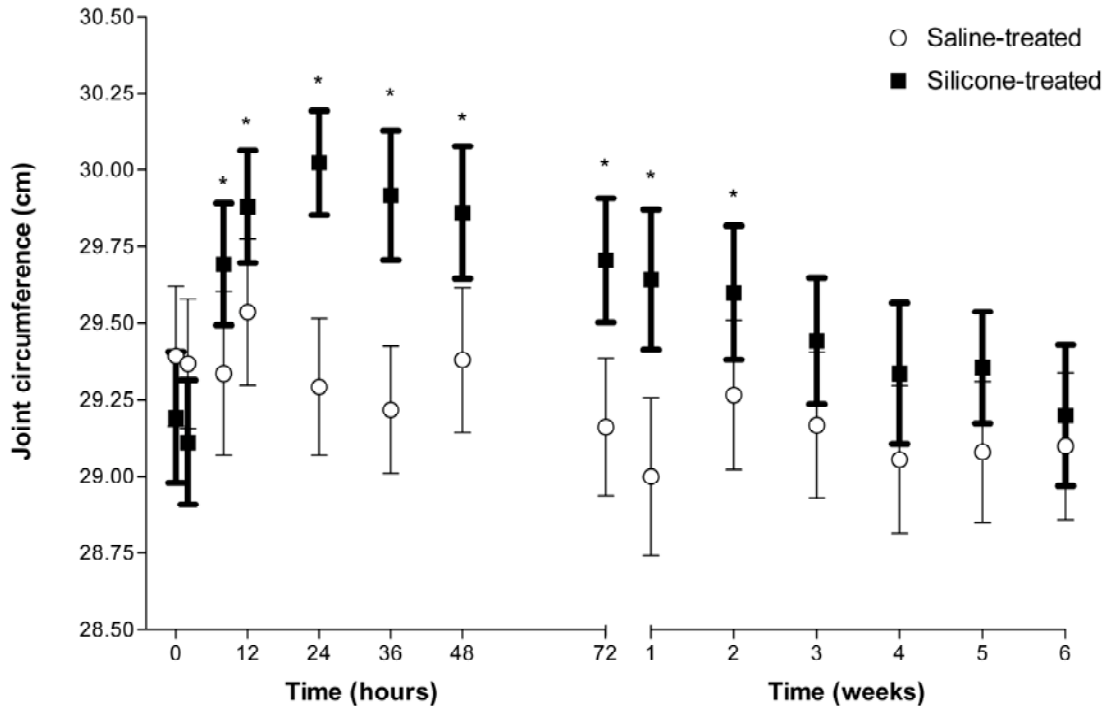


Figure 2.1. Mean \pm SEM joint circumferences for silicone-treated and saline-treated carpi. An asterisk (*) denotes a significant ($p \leq 0.5$) increase in joint circumference for silicone-treated carpi over the circumference at time zero. There was no significant change over time for saline-treated carpi.

Table 2.2. Significant clinical variables associated with treatment reflected by 95% confidence intervals (CI) of relative risk estimates that exclude 1.0. Where time is a confounder, the adjusted relative risk (RRa) estimate is reported. Where time was not a confounder, the crude relative risk (RRc) estimate is reported.

Variable	RR	95% CI
Lameness	RRc = 2.02	1.76-2.31
Lameness after carpal flexion	RRc = 2.87	2.39 – 3.44
Pain elicited by carpal flexion	RRa = 1.35	1.25 – 1.47
Effusion	RRa = 5.25	3.72 – 7.41

Table 2.3 Frequencies of lameness, lameness following 60 second carpal flexion test, pain demonstrated with maximal carpal flexion, decreased range of motion, and effusion for saline-treated and silicone treated carpi prior to injection (0 hours) and serially from two hours to six weeks after injection. Two observers evaluated the categories at each time point.

Time after injection	Treatment	Lameness	Lameness w/ flexion	Pain w/ flexion	Decreased ROM	Effusion
0 hours	Saline	0	0	0	0	0
	Silicone	0	0	0	0	0
2 hours	Saline	0	0	0	0	5
	Silicone	4	3	0	0	8
8 hours	Saline	1	1	0	0	9
	Silicone	13	13	10	1	16
12 hours	Saline	1	1	0	0	9
	Silicone	10	12	11	0	16
24 hours	Saline	0	0	0	0	8
	Silicone	13	14	9	0	16
36 hours	Saline	0	2	0	0	7
	Silicone	9	13	5	0	16
48 hours	Saline	0	0	0	0	7
	Silicone	11	12	4	0	15
72 hours	Saline	1	2	0	0	8
	Silicone	11	13	6	0	16
1 week	Saline	0	0	0	0	3
	Silicone	9	14	6	0	16
2 weeks	Saline	0	0	0	0	5
	Silicone	5	13	3	0	16
3 weeks	Saline	0	0	0	0	4
	Silicone	7	12	2	0	15
4 weeks	Saline	0	0	0	0	3
	Silicone	10	10	2	0	14
5 weeks	Saline	0	0	0	0	4
	Silicone	6	9	2	0	16
6 weeks	Saline	0	0	0	0	5
	Silicone	6	9	0	0	15

2.3.3 Radiography - Radiographic examination of saline-treated and silicone-treated limbs did not reveal the presence of any osseous abnormalities. The frequency of radiographic evidence of effusion was not significantly different between saline-treated carpi (2/8) and silicone-treated carpi (4/8).

2.3.4 Synovial Fluid - At time zero (immediately prior to treatment), 13/16 synovial fluid samples had a normal (≤ 500 cells/ μ L) total nucleated cell count. The remaining three synovial fluid samples had 600 – 700 cells/ μ L. Fifteen of 16 samples had a protein concentration of less than 2.5 g/dL. One sample had a protein concentration of 2.7 g/dL. The total nucleated cell count for this sample was normal. All four joints with elevations in synovial fluid parameters had been randomly selected to serve as a saline-treated joint. Thirteen of 16 samples were judged to have a good mucin clot. Three of 16 samples were judged to have a fair mucin clot.

All synovial fluid samples from saline-treated carpi at the conclusion of the study had a protein concentration of less than 2.5 g/dL. Total nucleated cell counts were normal in 6/8 carpi and abnormal in 2/8 carpi. Abnormal values were 700 cells/ μ L and 1,300 cells/ μ L. All synovial fluid samples from saline-treated joints were judged to have a good mucin clot. The cytologic exam revealed no apparent cytologic abnormalities in all saline-treated carpi.

All synovial fluid samples from silicone-treated carpi at the conclusion of the study had a protein concentration of less than 2.5 g/dL. Total nucleated cell counts were normal in 4/8 silicone-treated carpi and abnormal in 4/8 silicone-treated carpi. The frequency of abnormal total nucleated cell counts was not different from saline-treated carpi. Abnormal values ranged from 600 – 1,300 cells/ μ L. Six of eight synovial fluid samples from silicone-treated joints were judged to have a good mucin clot. Two of eight synovial fluid samples from silicone-treated joints were judged to have a fair mucin clot. There was no significant difference in frequency of good vs. fair mucin clots between

saline-treated and silicone-treated carpi. Cytologic exam revealed the presence of refractile cytoplasmic vacuoles within macrophages in 5/8 samples (Figure 2.2).

2.3.5 Synovial Membrane - No gross abnormalities were observed in any of the saline-treated or silicone-treated joints. Six tissue samples from saline-treated joints were evaluated. The frequencies of histologic grades are listed in Table 2.4. The modes of histologic grades are listed in Table 2.5. There was a significant difference in the distribution of the scores for the histologic assessment of the synovium with three being the most frequent score for silicone-treated carpi and zero being the most frequent score for saline-treated carpi. The remaining two tissue samples were considered inadequate for evaluation. Figures 2.3, 2.4, 2.5 and 2.6 are examples of histologic grades 0, 1, 2, and 3 respectively.

Table 2.4 Frequencies of histologic grades for synovial membrane, cartilage stained with hematoxyline and eosin (H & E), and cartilage stained with safranin-O from saline-treated and silicone-treated middle carpal joints. Frequencies of histologic grades for axillary lymph nodes from limbs with saline-treated and silicone-treated carpi.

Treatment	Synovial Membrane				Cartilage (H & E)			Cartilage (Safranin -O)			Lymph Node		
	0	1	2	3	0	1	2	0	1	2	0	1	2
Saline	4	2	0	0	7	1	0	7	1	0	5	2	0
Silicone	0	1	3	4	6	2	0	6	2	0	3	4	1

Table 2.5 Modes of histologic grades for synovial membrane, articular cartilage stained with hematoxylin & eosin (H&E), and articular cartilage stained with safranin-O from saline-treated and silicone-treated middle carpal joints. Modes of histologic grades for axillary lymph nodes from limbs with saline-treated and silicone-treated carpi.

Treatment	Synovial Membrane	Cartilage (H & E)	Cartilage (Safranin-O)	Lymph Node
Saline	0	0	0	0
Silicone	3	0	0	1

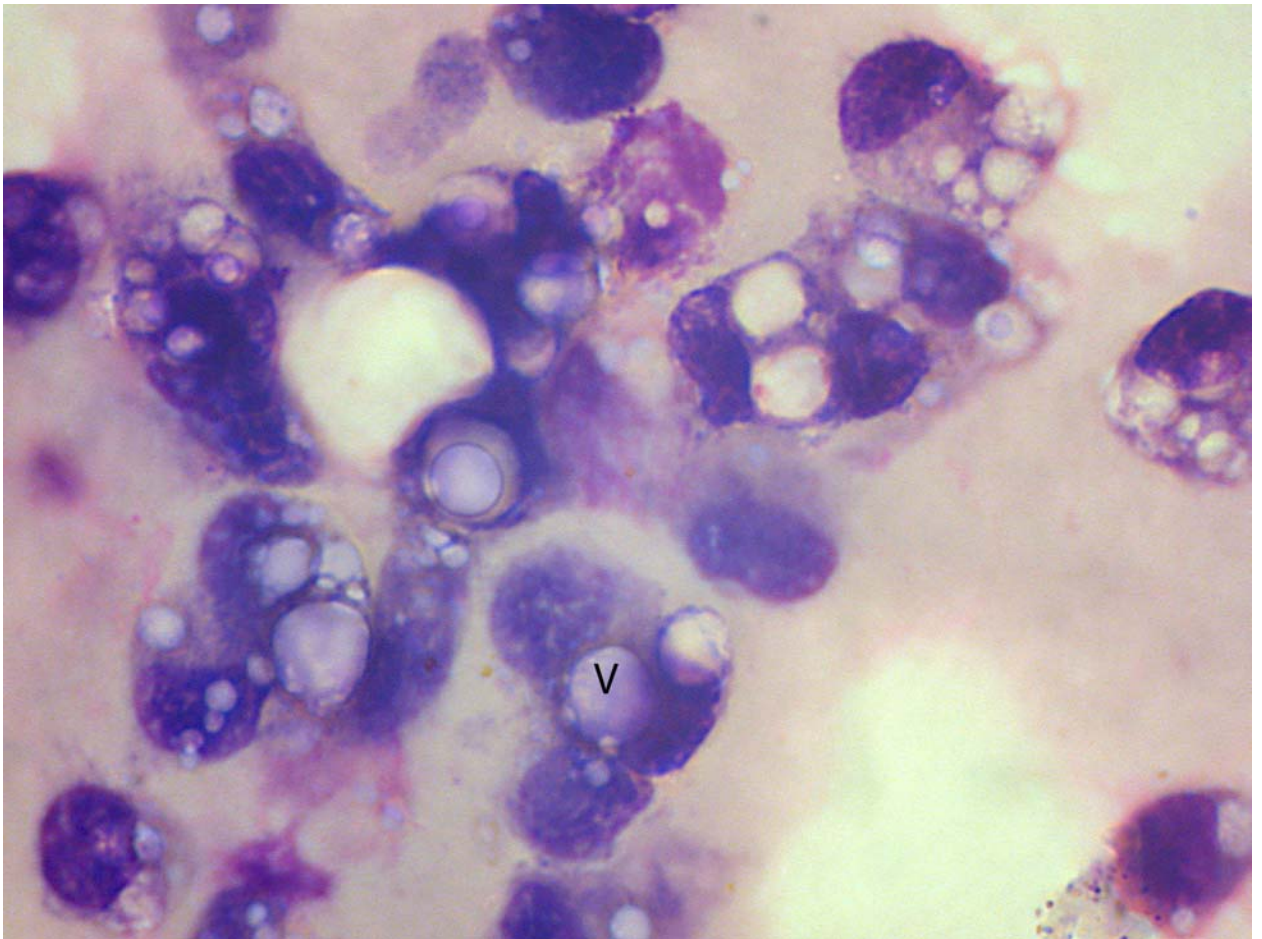


Figure 2.2. Photomicrograph of synovial fluid from a silicone-treated middle carpal joint illustrating distinct cytoplasmic vacuoles (V) containing silicone within macrophages. Modified polychrome methylene blue-eosin stain. 198x magnification.

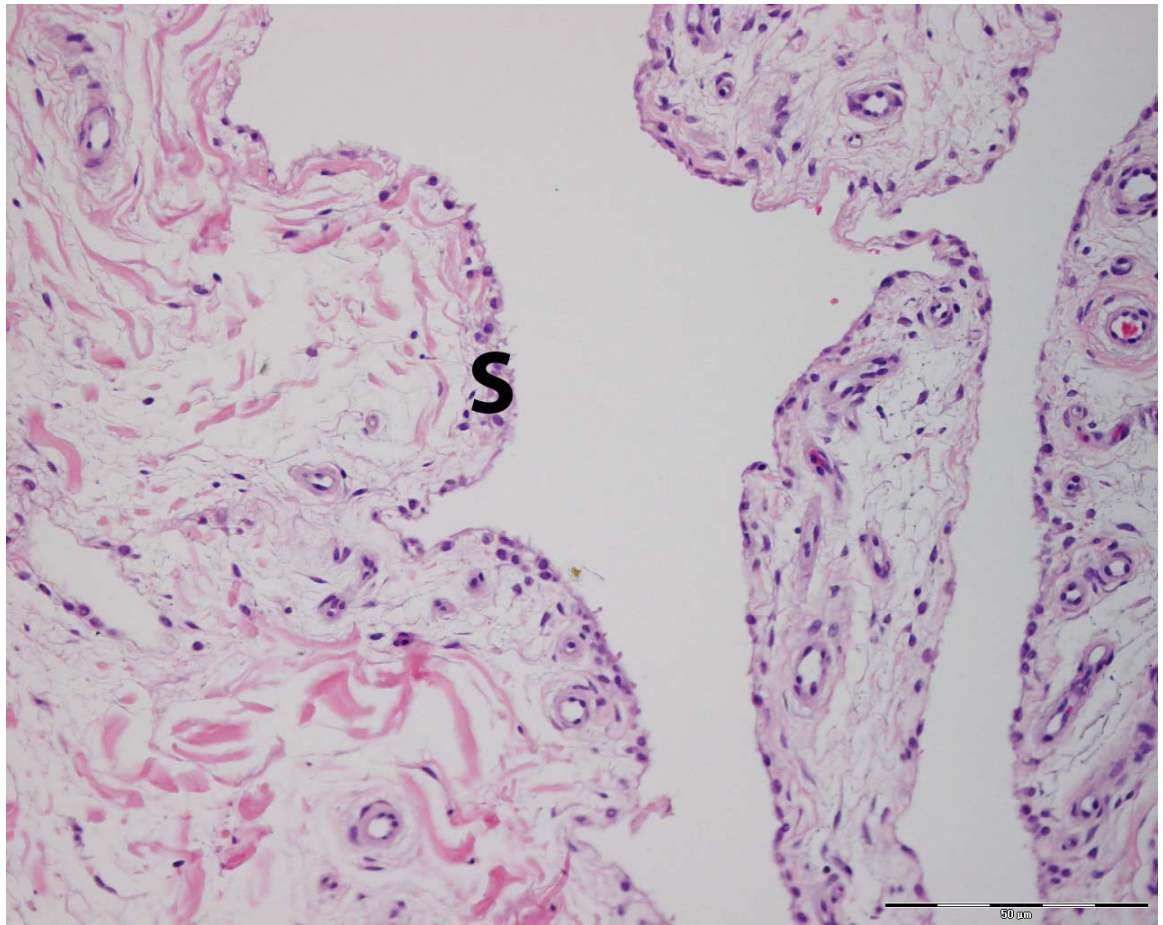


Figure 2.3. Photomicrograph of synovial membrane from a saline-treated joint that was graded 0. The synovium (S) is comprised of a single layer of cells. Hematoxylin & eosin. 20x magnification. Magnification bar is 50 μm .

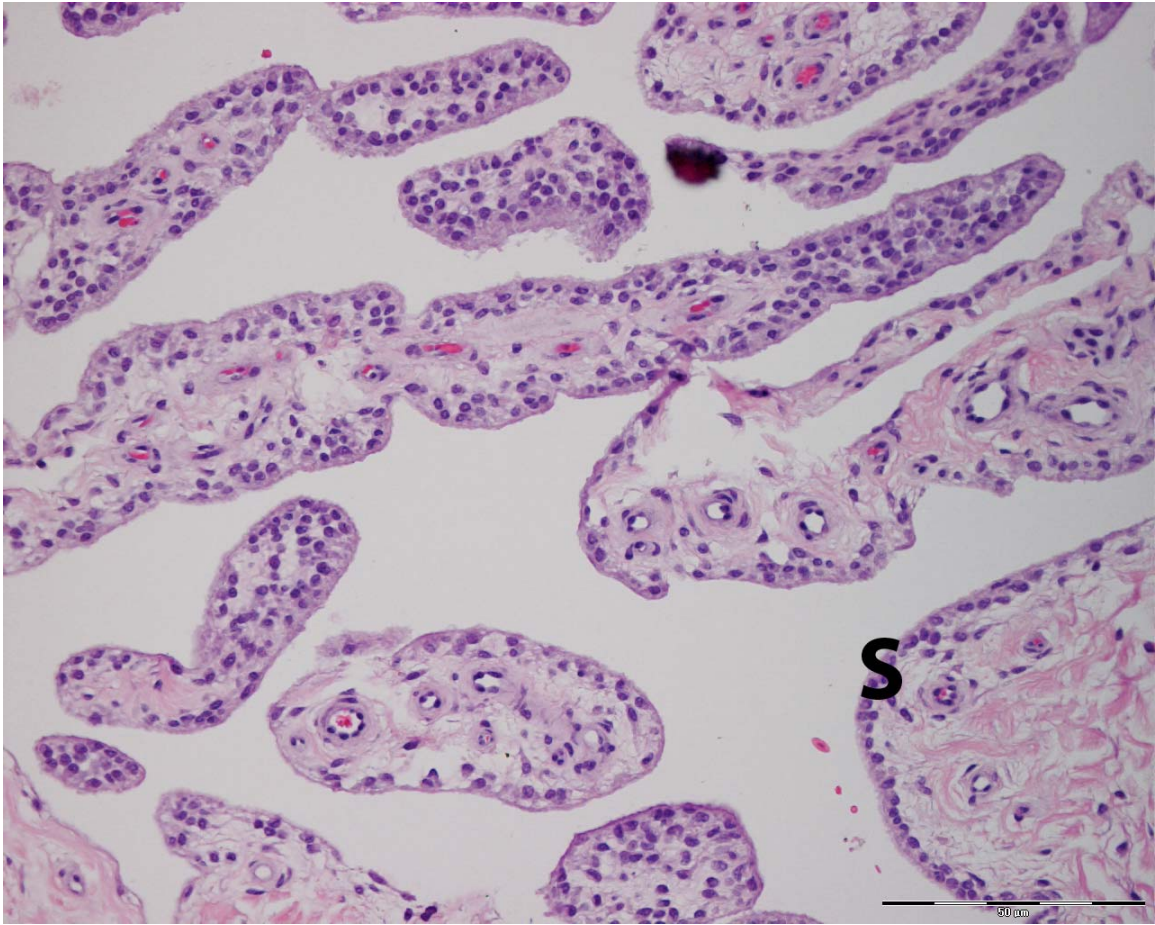


Figure 2.4. Photomicrograph of synovial membrane from a silicone-treated joint that was graded 1. There is slight hypertrophy/hyperplasia of the synovium (S). Hematoxylin & eosin. 20x magnification. Magnification bar is 50 μm .

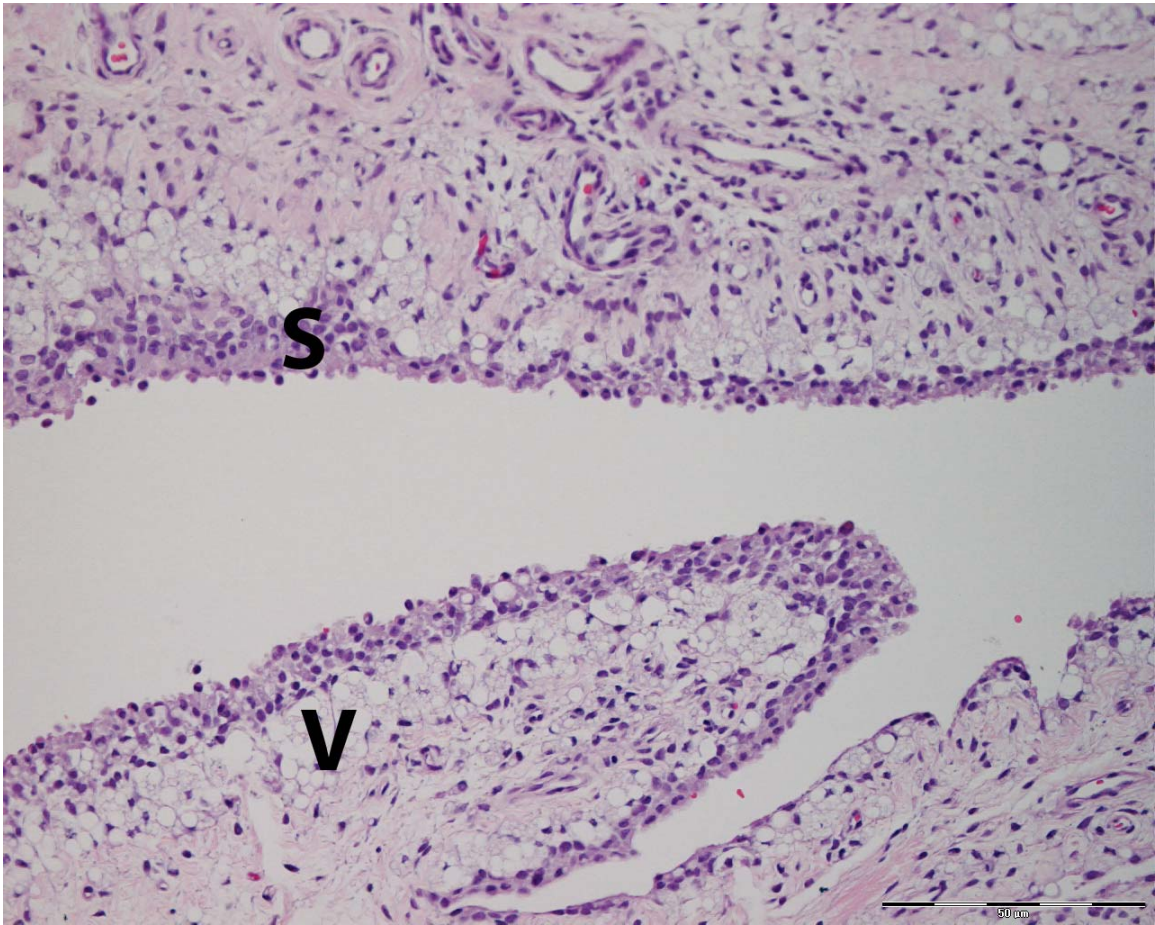


Figure 2.5. Photomicrograph of synovial membrane from a silicone-treated joint that was graded 2. There is hypertrophy/hyperplasia of the synovium (S) along with moderate accumulation of distended, vacuolated cells (V) containing silicone beneath the synovium. Hematoxylin & eosin. 20x magnification. Magnification bar is 50 μ m.

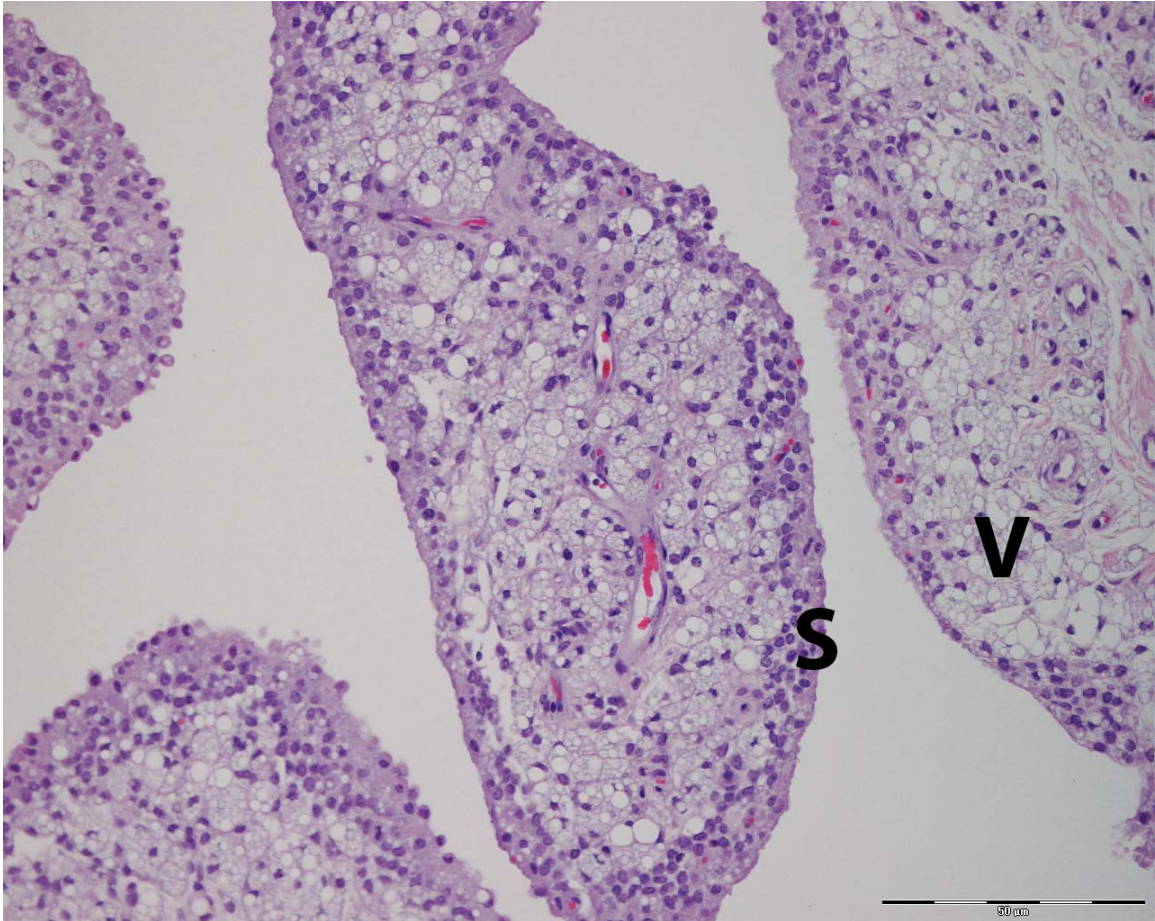


Figure 2.6. Photomicrograph of synovial membrane from a silicone-treated joint that was graded 3. There is hypertrophy/hyperplasia of the synovium (S) along with marked accumulation of distended, vacuolated cells (V) containing silicone beneath the synovium. Hematoxylin & eosin. 20x magnification. Magnification bar is 50 μ m.

2.3.6 Articular Cartilage - No gross abnormalities were observed in any of the saline-treated or silicone-treated joints. The frequencies of histologic grades are listed in Table 2.4. The modes of histologic grades are listed in Table 2.5. There was no significant difference in the distribution of scores for the histologic assessment of the articular cartilage. Figures 2.7 and 2.8 are examples of histologic grades 0.

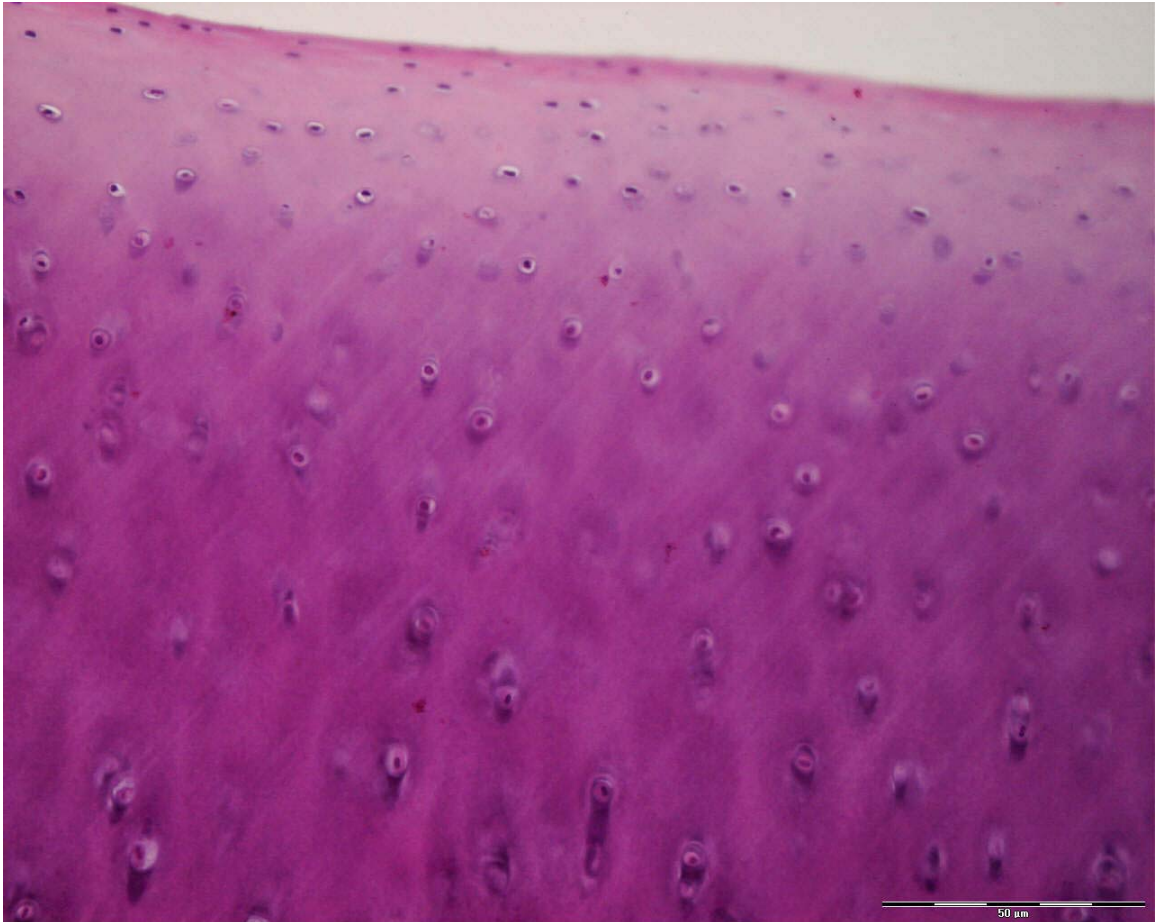


Figure 2.7. Photomicrograph of articular cartilage that was graded 0. Hematoxylin & eosin. 20x magnification. Magnification bar is 50 μm .




Figure 2.8. Photomicrograph of articular cartilage that was graded 0. Safranin O. 20x magnification. Magnification bar is 50 μm .

2.3.7 Axillary Lymph Nodes - No gross abnormalities were observed in any of the saline-treated or silicone-treated joints. The frequencies of histologic grades are listed in Table 2.4. The modes of histologic grades are listed in Table 2.5. There was no significant difference in the distribution of scores for the histologic assessment of the axillary lymph nodes.

2.4 Discussion

Intra-articular administration of silicone polymer had no apparent systemic effects. All of the horses had a normal rectal temperature, heart rate and respiratory rate prior to injection and 24, 48 and 72 hours after injection. Appetite and attitude were

considered normal throughout the duration of the study. Fever, depression and/or inappetence have been reported with experimental models of synovitis in horses (10, 11). Acute systemic effects following intra-articular administration of liquid silicone have not been reported in any species. Acute, pulmonary edema has been reported following inadvertent intravascular injection of liquid silicone in a human (12).

Silicone-treated carpi developed clinical signs of acute synovitis. Effusion and joint pain with lameness are typical manifestations (2). Joint circumference was used as an objective measurement of effusion. There was a significant increase in joint circumference for silicone-treated carpi from 8 hours after injection to 2 weeks after injection. Silicone-treated middle carpal joints were found to have 5.25 times the risk of developing effusion when compared to saline-treated middle carpal joints. In addition to an increased risk for effusion, there was a significant association between silicone-treated limbs and lameness, lameness after flexion of the carpus, and pain elicited upon maximal flexion of the carpus. Determination of synovial fluid protein concentration and nucleated cell count while the horses were displaying clinical signs of acute synovitis may have been helpful to demonstrate the extent of the synovitis; however, this could have altered the results at the conclusion of the study by removing silicone from the joint and potentially altering subsequent histologic findings. Synovial membrane biopsy and histologic examination could also have been useful to characterize the degree of synovitis.

At time zero (immediately prior to injection), synovial fluid from four carpi had abnormal values. These carpi had been randomly selected to receive saline prior to this determination. The decision to include these carpi in the final data decreases the type I

error, and therefore, would bias the data towards accepting the null hypothesis. Thus, the confidence in our findings of a difference between the two treatments is enhanced.

At the conclusion of the study, synovial fluid samples from silicone-treated middle carpal joints had a normal protein concentration. Four of eight silicone-treated middle carpal joints had an increased total nucleated cell count (600-1,300 cells/ μ L). This is an interesting finding because all of the horses still had effusion present in the silicone-treated carpus at the conclusion of the study. In addition, five horses were considered by at least one investigator to have a baseline lameness involving the silicone-treated limb, and six horses were responsive to flexion of the silicone-treated carpus. The findings of effusion, lameness, and pain on flexion of a joint are typical for synovitis; however, synovial fluid variables did not support this. Total protein is expected to increase with synovitis, and active synovitis generally yields total nucleated cell counts of 5,000 to 10,000 cells/ μ L (13).

At the conclusion of the study, synovial fluid samples from saline-treated middle carpal joints had a normal protein concentration. This is an expected result because saline has not been reported to cause any chronic increases in synovial fluid protein concentration. The increase in total nucleated cell count in two horses (700 – 1,300 cells/ μ L) was unexpected. Intra-articular administration of saline has been reported to cause an increase in the total nucleated cell count of synovial fluid; however, this increase does not persist beyond seven days after injection (14). Both of the aforementioned horses began the study with an increased total nucleated cell count at time zero. It is possible that these are normal values for these individual horses. Neither of these horses was considered to be lame by either investigator at the conclusion of the

study; however, it is possible albeit unlikely that either horse could have sustained an injury while on pasture that is reflected in the increase in total nucleated cell count.

Silicone was presumably found within the synovial fluid in the majority of treated carpi six weeks after injection. The large, clear vacuoles within macrophages were not found in synovial fluid from any of the saline-treated carpi. Definitive identification of silicone would have required spectroscopy because silicone does not retain stain (15, 16). Our results agree with a previous study in which silicone injected into rabbit knee joints was present within synovial fluid at least six weeks after injection (17). This differs from previous reports in which silicone was not found within rabbit synovial fluid one week after injection (8). The differences between studies may be due to the difference in the type of silicone used or could be due to individual animal variation in rate of phagocytosis and clearance of silicone from synovial fluid.

All synovial fluid samples taken before injection of silicone and synovial fluid samples taken at the conclusion of the study from both saline-treated and silicone-treated middle carpal joints were judged to have a fair to good mucin clot quality. The test for mucinous precipitate quality serves as a reliable index of synovial fluid hyaluronic acid polymerization and a qualitative measure of its concentration in normal and pathologic synovial fluids (18). Normal joints have a good to fair mucin clot quality (18). In our study, all synovial fluid samples were judged to have a normal mucin clot quality; however, this does not rule out joint inflammation. Mucin clot quality is usually normal (judged good to fair) in degenerative joint disease, osteochondritis dissecans, and chronic traumatic arthritis (13, 19). It has been suggested that there is not a strong association between degree of inflammation and mucin clot quality (13).

Hypertrophy or hyperplasia of the synovium is one of the histologic signs of synovitis. Acute synovitis is generally characterized by increased vascularization, edema, inflammatory cell infiltration, increased synoviocyte numbers (hyperplasia) and villous hypertrophy (20). Chronic synovitis is characterized by cellular and fibrovascular proliferation in the subintima (2). None of the synovial membrane samples had histologic signs of acute synovitis. This is not unexpected because these samples were collected six weeks after intra-articular administration of silicone which is beyond the expected time frame of acute disease. The hypertrophy/hyperplasia noted in the synovium of one saline-treated joint and one silicone-treated joint was considered to be mild and did not have the accompanying fibrous and vascular proliferation that would be expected with chronic synovitis. The remaining silicone-treated joints had mild hyperplasia/hypertrophy of the synovium in addition to accumulation of vacuolated cells in the subsynovial layer. These samples were also lacking the fibrous and vascular proliferation that would be expected with chronic synovitis. It appears that the silicone polymer is incorporated into the subsynovium without inciting a significant chronic inflammatory response. This is an interesting finding because all horses still had effusion present in silicone-treated carpi at the conclusion of the study. In addition, five horses were considered by at least one investigator to have a baseline lameness affecting the silicone-treated limb, and six horses were responsive to flexion of the silicone-treated carpus. The mild histologic findings of inflammation correlate with the normal protein concentration and normal to mildly increased total nucleated cell count of synovial fluid from silicone-treated carpi.

The findings of minimal inflammation are consistent with previous reports that liquid silicone causes only mild inflammation in surrounding tissue (6-8, 15, 21). However, our findings are in contrast to a study that investigated the effects of liquid silicone on the synovial membrane in the equine middle carpal joint. That study reported a marked foreign body reaction with fibrin deposition and eosinophilic infiltration four weeks after administration (4). It is possible that the product used in the earlier study differed from ours in purity and/or sterility.

There was no difference between silicone-treated and saline-treated carpi for the subjective assessment of safranin O staining intensity. Safranin O stains both chondroitin sulfate and keratosulfate and, thereby, provides a semiquantitative assessment of the amount of glycosaminoglycans present in articular cartilage (22). There was no evidence of glycosaminoglycan depletion, or chondrocyte necrosis or fibrillation and erosion in any of the articular cartilage samples. It is presumed that an inflamed synovial membrane releases degradative enzymes and cytokines that can lead to cartilage degradation (13). It has been demonstrated in an experimental model of arthritis that synovitis can result in pathologic changes in articular cartilage (22). It is probable that the degree of acute synovitis caused by a single intra-articular administration of silicone was not sufficient to cause cartilage degradation. This is substantiated by the minimal inflammatory response demonstrated in the synovial membrane. It is possible, that administration of liquid silicone into a previously inflamed joint could worsen the degree of existing synovitis and result in cartilage degradation. Alternatively, the interval between administration of the silicone and post-mortem exam may not have been of sufficient length for cartilage degradation to occur.

Axillary lymph nodes from silicone-treated limbs most frequently demonstrated mild accumulation of vacuolated cells in the lymph nodes sinuses; however, microscopic examination of axillary lymph nodes did not definitively determine the presence of silicone in the lymph nodes from saline-treated or silicone-treated limbs. Droplets of silicone smaller than 10 μm can be phagocytosed by macrophages (21). In the case of silicone lymphadenopathy, it is plausible that macrophages containing silicone enter the lymphatics contained within the synovial membrane and travel to the lymph nodes draining the treated limb. Once deposited in the lymph node, the cells containing liquid silicone will appear to have clear, round to oval vacuoles of varying sizes (15). The presence of vacuolated cells within the lymph node sinuses is not specific for silicone. This could also be due to the presence of fat. In routine histologic sections, lipid is extracted during tissue processing leaving a large, unstained space (23). Fat accumulation could be ruled out by staining with oil red O solution (24). Alternatively, positive identification of silicone could be made by scanning electron microscopy or energy dispersive x-ray analysis (15). It is possible that the six-week interval between injection and histologic examination of the axillary lymph node was not of sufficient duration for the silicone to migrate via lymphatics to the axillary lymph node. It has been reported that silicone migrates slowly through lymphatics. Silicone lymphadenopathy was discovered in axillary lymph nodes six to ten years after breast implantation and four to eight years after placement of elastomer finger joint prosthesis in humans (15). It is also possible that a larger volume or multiple administrations of intra-articular silicone may be required for lymphatic migration in the horse.

This study did not investigate the efficacy of liquid silicone as an exogenous lubricant; however, it is unlikely to function in that capacity. Lubrication of articular cartilage (at low loads) and soft tissues is accomplished by the binding of lubricin and HA. These molecules prevent direct contact of opposing surfaces and thereby, decrease the coefficient of friction between two opposing surfaces (13). It has been demonstrated that liquid silicone is phagocytosed by intrasynovial macrophages and subsequently removed from synovial fluid. Following removal from the synovial fluid, it would be unable to function as a lubricant.

The results of this study indicate that a single administration of two mLs of liquid silicone causes an acute synovitis when injected into the equine middle carpal joint. Silicone appears to be phagocytized by macrophages and incorporated in the subsynovium with minimal inflammatory response; however, clinical signs of joint disease (effusion, lameness) persist. A single intra-articular administration of two mLs of liquid silicone did not result in appreciable articular cartilage damage six weeks after administration. Due to the degree of acute synovitis, liquid silicone is not recommended for intra-articular use in the horse.

2.5 Product Information

^a Rompun®, Bayer Corporation, Shawnee Mission, KS

^b Wedgewood Pharmacy, Sewell, NJ

^c Beuthanasia®-D Special, Schering-Plough Animal Health Corp., Union, NJ

^d Baker System 911 Plus Hematology Analyzer, Biochem Immunosystems, Inc., Allentown, PA

^e Cytopspin 3, Shandon Life Sciences, International, Astmoor, England

^f Hema-Tek® Stain Pak, Hema-Tek 1000, Miles Laboratories, Inc., Naperville, IL

^g SAS v 8.2, SAS Institute, Cary, NC

2.6 References

1. Rossdale P D, et al. Epidemiological study of wastage among racehorses 1982 and 1983. *Vet Rec* 1985; 116(3): p. 66-9.
2. Todhunter RJ, Lust G. Pathophysiology of Synovitis: Clinical Signs and Examination in Horses. *Compend Contin Educ Pract Vet* 1990; 12(7): p. 980-992.
3. McIlwraith CW. Current concepts in equine degenerative joint disease. *J Am Vet Med Assoc* 1982; 180(3): p. 239-50.
4. Riddle WE, Jr., Wheat JD. Liquid silicone for intra-articular use in the horse. *J Am Vet Med Assoc* 1967; 155(8): p. 1367-9.
5. Braley SA. The use of silicones in plastic surgery. A retrospective view. *Plast Reconstr Surg* 1973; 51(3): p. 280-8.
6. Helal B, Karadi BS. Artificial lubrication of joints: use of silicone oil. *Ann Phys Med* 1968; 9(8): p. 334-40.
7. Helal B, Cozen L, Kramer L. Silicone injection of joints. Experimental and clinical trials. *Int Surg* 1970; 54(5): p. 317-22.
8. Wright V, et al. Evaluation of silicone as an artificial lubricant in osteoarthrotic joints. *Br Med J* 1971; 2(758): p. 370-3.
9. *Guide for Veterinary Service and Judging of Equestrian Events*. 4th ed. 1991, Lexington: American Association of Equine Practitioners.
10. Palmer JL, Bertone AL. Experimentally-induced synovitis as a model for acute synovitis in the horse. *Equine Vet J* 1994; 26(6): p. 492-5.
11. Cornelissen BP, et al. Experimental model of synovitis/capsulitis in the equine metacarpophalangeal joint. *Am J Vet Res* 1998; 59(8): p. 978-85.
12. Ellenbogen R, Rubin L. Injectable fluid silicone therapy. Human morbidity and mortality. *Jama* 1975; 234(3): p. 308-9.
13. McIlwraith CW, Trotter GW, *Joint Disease in the Horse*. 1996, Philadelphia: W.B. Saunders Company.
14. Wagner AE, McIlwraith CW, Martin GS. Effect of intra-articular injection of orgotein and saline solution on equine synovia. *Am J Vet Res* 1982; 43(4): p. 594-7.
15. Travis WD, Balogh K, Abraham JL. Silicone granulomas: report of three cases and review of the literature. *Hum Pathol* 1985; 16(1): p. 19-27.

16. Nosanchuk JS. Injected dimethylpolysiloxane fluid: a study of antibody and histologic response. *Plast Reconstr Surg* 1968; 42(6): p. 562-6.
17. Donahue WC, Nosanchuk JS, Kaufer H. Effect and fate of intra-articular silicone fluid. *Clin Orthop* 1971; 77: p. 305-10.
18. Van Pelt R. Properties of Equine Synovial Fluid. *J Am Vet Med Assoc* 1962; 141(9): p. 1051-1061.
19. Van Pelt R. Interpretation of Synovial Fluid Findings in the Horse. *J Am Vet Med Assoc* 1974; 165(1): p. 91-95.
20. Palmer JL, Bertone AL. Joint structure, biochemistry and biochemical disequilibrium in synovitis and equine joint disease. *Equine Vet J* 1994; 26(4): p. 263-77.
21. Murray DG. The fate of liquid silicone in the rabbit knee joint. *Clin Orthop* 1972; 87: p. 275-80.
22. McIlwraith CW, Van Sickle DC. Experimentally induced arthritis of the equine carpus: histologic and histochemical changes in the articular cartilage. *Am J Vet Res* 1981; 42(2): p. 209-17.
23. Burkitt HG, Young B, Heath JW, *Wheater's Functional Histology*. Third ed. 1993, New York: Churchill Livingstone, Inc. 407.
24. WebPath: Internet Pathology Lab. 2003: <http://www-medlib.med.utah.edu/WebPath/webpath.html>.

SUMMARY

Intra-articular administration of two mLs of liquid silicone (1,000 cs) into the normal equine middle carpal joint resulted in a significant increase in joint circumference for silicone-treated carpi from eight hours after injection to two weeks after injection. Intra-articular administration of two mLs of 0.9% NaCL did not result in a significant increase in joint circumference. The mean \pm SD heart rate, rectal temperature, and respiratory rate of treated horses were normal throughout the study. There was a significant association between silicone-treated limbs and lameness, lameness after flexion, pain elicited upon maximal flexion of carpus, and middle carpal effusion in silicone-treated limbs. The greatest association was found between silicone treatment and effusion. Time was found to be a confounder for effusion and pain elicited by maximal carpal flexion. There was no association between treatment and decreased range of motion during carpal flexion. Radiographic examination did not reveal the presence of osseous abnormalities in silicone-treated or saline-treated carpi. Radiographic evidence of effusion was present in 4/8 silicone-treated carpi and 2/8 saline-treated carpi; however, the frequency of radiographic evidence of effusion was not significantly different between saline-treated carpi and silicone-treated carpi. All synovial fluid samples from saline-treated carpi at the conclusion of the study had a protein concentration of less than 2.5 g/dL. Total nucleated cell counts in saline-treated carpi were normal in 6/8 carpi and increased in 2/8 carpi. All synovial fluid samples from silicone-treated carpi at the conclusion of the study had a protein concentration of less than 2.5 g/dL. Total nucleated cell counts were normal in 4/8 silicone-treated carpi and increased in 4/8 silicone-treated carpi. The frequency of abnormal total nucleated

cell counts was not different from saline-treated carpi. Cytologic exam of synovial fluid revealed the presence of cytoplasmic vacuoles containing silicone within macrophages in 5/8 silicone-treated carpi. There was no significant difference in frequency of good vs. fair mucin clots between saline-treated and silicone-treated carpi. No gross abnormalities were observed in any of the saline-treated or silicone-treated joints. Synovial membrane from silicone-treated carpi most commonly demonstrated mild hyperplasia/hypertrophy of the synovium along with marked subsynovial vacuolization of silicone. Synovial membrane from saline-treated carpi was normal in most carpi. Articular cartilage stained with H & E and articular cartilage stained with safranin O was normal in most saline-treated and silicone-treated carpi. Axillary lymph nodes from the limbs with silicone-treated carpi most commonly demonstrated mild accumulation of vacuolated cells in the lymph node sinuses. Axillary lymph nodes were normal in most limbs with saline-treated carpi. There was no significant difference between saline-treated and silicone-treated carpi in the distribution of scores for the histologic assessment of the articular cartilage or axillary lymph nodes.

The results of this study indicate that a single administration of two mLs of liquid silicone causes an acute synovitis when injected into the equine middle carpal joint. Silicone appears to be phagocytized by macrophages and incorporated in the subsynovium with minimal inflammatory response; however, clinical signs of joint disease (effusion, lameness) persist. A single intra-articular administration of two mLs of liquid silicone (1,000 cs) did not result in appreciable articular cartilage damage six weeks after administration. Due to the degree of acute synovitis, liquid silicone is not recommended for intra-articular use in the horse.

BIBLIOGRAPHY

- Allevato MA, et al. Complications following industrial liquid silicone injection. *Int J Dermatol* 1996; 35(3): p. 193-5.
- Alwan WH, et al. Interleukin-1-like activity in synovial fluids and sera of horses with arthritis. *Res Vet Sci* 1991; 51(1): p. 72-7.
- Ben-Hur N, et al. Local and systemic effects of dimethylpolysiloxane fluid in mice. *Plast Reconstr Surg* 1967; 39(4): p. 423-6.
- Bigata X, et al. Adverse granulomatous reaction after cosmetic dermal silicone injection. *Dermatol Surg* 2001; 27(2): p. 198-200.
- Billinghurst RC, Fretz PB, Gordon J R. Induction of intra-articular tumour necrosis factor during acute inflammatory responses in equine arthritis. *Equine Vet J* 1995; 27(3): p. 208-16.
- Braley SA. The use of silicones in plastic surgery. A retrospective view. *Plast Reconstr Surg* 1973; 51(3): p. 280-8.
- Burkitt HG, Young B, Heath JW, *Wheater's Functional Histology*. Third ed. 1993, New York: Churchill Livingstone, Inc. 407.
- Caron JP. Synovial Joint Biology and Pathobiology. In: *Equine Surgery*. Auer JA, Stick JA, Editors. 1999, W.B. Saunders Company: Philadelphia. p. 665-678.
- Caron JP, Eberhart SW, Nachreiner R. Influence of polysulfated glycosaminoglycan on equine articular cartilage in explant culture. *Am J Vet Res* 1991; 52(10): p. 1622-5.
- Caron JP, Toppin DS, Block JA. Effect of polysulfated glycosaminoglycan on osteoarthritic equine articular cartilage in explant culture. *Am J Vet Res* 1993; 54(7): p. 1116-21.
- Chunekamrai S, et al. Changes in articular cartilage after intra-articular injections of methylprednisolone acetate in horses. *Am J Vet Res* 1989; 50(10): p. 1733-41.
- Cornelissen BP, et al. Experimental model of synovitis/capsulitis in the equine metacarpophalangeal joint. *Am J Vet Res* 1998; 59(8): p. 978-85.
- Donahue WC, Nosanchuk JS, Kaufer H. Effect and fate of intra-articular silicone fluid. *Clin Orthop* 1971; 77: p. 305-10.

Ellenbogen R, Rubin L. Injectable fluid silicone therapy. Human morbidity and mortality. *Jama* 1975; 234(3): p. 308-9.

Foland JW, et al. Effect of betamethasone and exercise on equine carpal joints with osteochondral fragments. *Vet Surg* 1994; 23(5): p. 369-76.

Frean SP, Lees P. Effects of polysulfated glycosaminoglycan and hyaluronan on prostaglandin E2 production by cultured equine synoviocytes. *Am J Vet Res* 2000; 61(5): p. 499-505.

Frisbie DD, et al. Effects of triamcinolone acetonide on an in vivo equine osteochondral fragment exercise model. *Equine Vet J* 1997; 29(5): p. 349-59.

Glade MJ. Polysulfated glycosaminoglycan accelerates net synthesis of collagen and glycosaminoglycans by arthritic equine cartilage tissues and chondrocytes. *Am J Vet Res* 1990; 51(5): p. 779-85.

Guerrissi J, Bejar A. Massive injections of adulterated liquid silicone: local complications and development of autoimmune diseases. *Ann Plast Surg* 1998; 41(5): p. 572-3.

Guide for Veterinary Service and Judging of Equestrian Events. 4th ed. 1991, Lexington: American Association of Equine Practitioners.

Gustafson SB, et al. Further investigations into the potentiation of infection by intra-articular injection of polysulfated glycosaminoglycan and the effect of filtration and intra-articular injection of amikacin. *Am J Vet Res* 1989; 50(12): p. 2018-22.

Gustafson SB, McIlwraith CW, Jones RL. Comparison of the effect of polysulfated glycosaminoglycan, corticosteroids, and sodium hyaluronate in the potentiation of a subinfective dose of *Staphylococcus aureus* in the midcarpal joint of horses. *Am J Vet Res* 1989; 50(12): p. 2014-7.

Helal B, Cozen L, Kramer L. Silicone injection of joints. Experimental and clinical trials. *Int Surg* 1970; 54(5): p. 317-22.

Helal B, Karadi BS. Artificial lubrication of joints: use of silicone oil. *Ann Phys Med* 1968; 9(8): p. 334-40.

May SA, Hooke RE, Lees P. The effect of drugs used in the treatment of osteoarthritis on stromelysin (proteoglycanase) of equine synovial cell origin. *Equine Vet J Suppl* 1988(6): p. 28-32.

McIlwraith CW. Current concepts in equine degenerative joint disease. *J Am Vet Med Assoc* 1982; 180(3): p. 239-50.

- McIlwraith CW. Diseases of Joint, Tendons, Ligaments, and Related Structures. In: *Adams' Lameness in Horses*. Stashak TS, Editor. 2002, Lippincott Williams & Wilkins: Baltimore. p. 459-644.
- McIlwraith CW, Trotter GW. *Joint Disease in the Horse*. 1996, Philadelphia: W.B. Saunders Company.
- McIlwraith CW, Van Sickle DC. Experimentally induced arthritis of the equine carpus: histologic and histochemical changes in the articular cartilage. *Am J Vet Res* 1981; 42(2): p. 209-17.
- Moses VS, et al. Effects of anti-inflammatory drugs on lipopolysaccharide-challenged and -unchallenged equine synovial explants. *Am J Vet Res* 2001; 62(1): p. 54-60.
- Murray DG. The fate of liquid silicone in the rabbit knee joint. *Clin Orthop* 1972; 87: p. 275-80.
- Nosanchuk JS. Injected dimethylpolysiloxane fluid: a study of antibody and histologic response. *Plast Reconstr Surg* 1968; 42(6): p. 562-6.
- Orenstein J M, et al. Microemboli observed in deaths following cardiopulmonary bypass surgery: silicone antifoam agents and polyvinyl chloride tubing as sources of emboli. *Hum Pathol* 1982; 13(12): p. 1082-90.
- Palmer JL, Bertone AL. Experimentally-induced synovitis as a model for acute synovitis in the horse. *Equine Vet J* 1994; 26(6): p. 492-5.
- Palmer JL, Bertone AL. Joint structure, biochemistry and biochemical disequilibrium in synovitis and equine joint disease. *Equine Vet J* 1994; 26(4): p. 263-77.
- Rashmir-Raven AM, et al. Inhibition of equine complement activity by polysulfated glycosaminoglycans. *Am J Vet Res* 1992; 53(1): p. 87-90.
- Richardson DW, Dodge GR. Effects of interleukin-1 beta and tumor necrosis factor-alpha on expression of matrix-related genes by cultured equine articular chondrocytes. *Am J Vet Res* 2000; 61(6): p. 624-30.
- Riddle WE, Jr., Wheat JD. Liquid silicone for intra-articular use in the horse. *J Am Vet Med Assoc* 1967; 155(8): p. 1367-9.
- Rees TD, et al. Visceral response to subcutaneous and intraperitoneal injections of silicone in mice. *Plast Reconstr Surg* 1967; 39(4): p. 402-10.
- Rossdale PD, et al. Epidemiological study of wastage among racehorses 1982 and 1983. *Vet Rec* 1985; 116(3): p. 66-9.

- Spiers S, et al. Cellular sources of proteolytic enzymes in equine joints. *Equine Vet J* 1994; 26(1): p. 43-7.
- Suominen MM, et al. Effects of intra-articular injections of bufexamac suspension on amphotericin B-induced aseptic arthritis in horses. *Am J Vet Res* 1999; 60(12): p. 1467-73.
- Todhunter PG, et al. Immunohistochemical analysis of an equine model of synovitis-induced arthritis. *Am J Vet Res* 1996; 57(7): p. 1080-93.
- Todhunter RJ, Lust G. Pathophysiology of Synovitis: Clinical Signs and Examination in Horses. *Compend Contin Educ Pract Vet* 1990; 12(7): p. 980-992.
- Travis WD, Balogh K, Abraham JL. Silicone granulomas: report of three cases and review of the literature. *Hum Pathol* 1985; 16(1): p. 19-27.
- Trotter GW, et al. Effects of intra-articular administration of methylprednisolone acetate on normal equine articular cartilage. *Am J Vet Res* 1991; 52(1): p. 83-7.
- Van Pelt R. Interpretation of Synovial Fluid Findings in the Horse. *J Am Vet Med Assoc* 1974; 165(1): p. 91-95.
- Van Pelt R. Properties of Equine Synovial Fluid. *J Am Vet Med Assoc* 1962; 141(9): p. 1051-1061.
- Wagner AE, McIlwraith CW, Martin GS. Effect of intra-articular injection of orgotein and saline solution on equine synovia. *Am J Vet Res* 1982; 43(4): p. 594-7.
- WebPath: Internet Pathology Lab. 2003: <http://www-medlib.med.utah.edu/WebPath/webpath.html>
- Wright V, et al. Evaluation of silicone as an artificial lubricant in osteoarthrotic joints. *Br Med J* 1971; 2(758): p. 370-3.

VITA

Marilyn Louise Rumbaugh was born on March 30, 1972, in Reno, Nevada. She grew up in Reno, Nevada, and graduated from Hug High School in 1990. Marilyn attended the University of Nevada, Reno, earning a bachelor's degree in veterinary science in 1995. Marilyn earned the degree of Doctor of Veterinary Medicine in 1999 from The Ohio State University.

From July 1999 to June 2000, Dr. Rumbaugh did an internship in equine medicine and surgery at Pioneer Equine Hospital in Oakdale, California. Dr. Rumbaugh is currently completing her final year of a three-year equine surgery residency at Louisiana State University School of Veterinary Medicine in Baton Rouge, Louisiana, and will be awarded the degree of Master of Science in veterinary medical sciences in May 2003.